
Subject:	Locoregional Techniques for Treating Primary and Metastatic Liver Malignancies	Publish Date:	09/27/2023
Guideline #:	CG-SURG-78	Last Review Date:	05/11/2023
Status:	Revised		

Description

This document addresses locoregional therapies to treat primary or metastatic cancer of the liver. Treatment goals can be curative, palliative, as a bridge to liver transplantation or downstaging (become eligible for liver transplantation following initial treatment). Locoregional therapies may include any of the following ablative and arterially directed therapies:

- Ablative Therapy
 - Cryosurgical ablation, or cryotherapy
 - Microwave ablation (MWA)
 - Percutaneous ethanol injection (PEI)
 - Radiofrequency ablation (RFA)
 - Histotripsy
- Arterially directed therapy
 - Selective internal radiation therapy (SIRT); also known as transarterial radioembolization (TARE)
 - Transcatheter arterial chemoembolization (TACE)
 - Transcatheter arterial embolization (TAE)
 - Immunoembolization

Note: For related topics, please see the following:

- CG-SURG-61 Cryosurgical, Radiofrequency, Microwave or Laser Ablation to Treat Solid Tumors Outside the Liver
- RAD.00059 Catheter-based Embolization Procedures for Malignant Lesions Outside the Liver
- SURG.00126 Irreversible Electroporation
- TRANS.00008 Liver Transplantation

Clinical Indications

Medically Necessary:

Federal and State law, as well as contract language including definitions and specific coverage provisions/exclusions, and Medical Policy take precedence over Clinical UM Guidelines and must be considered first in determining eligibility for coverage. The member's contract benefits in effect on the date that services are rendered must be used. Clinical UM Guidelines, which address medical efficacy, should be considered before utilizing medical opinion in adjudication. Medical technology is constantly evolving, and we reserve the right to review and update Clinical UM Guidelines periodically. Clinical UM guidelines are used when the plan performs utilization review for the subject. Due to variances in utilization patterns, each plan may choose whether or not to adopt a particular Clinical UM Guideline. To determine if review is required for this Clinical UM Guideline, please contact the customer service number on the back of the member's card.

No part of this publication may be reproduced, stored in a retrieval system or transmitted, in any form or by any means, electronic, mechanical, photocopying, or otherwise, without permission from the health plan.

© CPT Only – American Medical Association

Healthy Blue is a Medicaid product offered by Missouri Care, Inc., a MO HealthNet Managed Care health plan contracting with the Missouri Department of Social Services. Healthy Blue is administered statewide by Missouri Care, Inc. and administered in the Kansas City service region by Missouri Care, Inc. in cooperation with Blue Cross and Blue Shield of Kansas City. Missouri Care, Inc. and Blue Cross and Blue Shield of Kansas City are both independent licensees of the Blue Cross and Blue Shield Association.

I. *Treatment of Hepatic Tumors (Primary or Metastatic)*

- A. Any of the following locally ablative techniques are considered **medically necessary** for individuals with *any* of the following conditions when *all* of the criteria below have been met:
1. Techniques
 - a. Cryosurgical ablation; **or**
 - b. Microwave ablation (MWA); **or**
 - c. Percutaneous ethanol injection (PEI); **or**
 - d. Radiofrequency (RFA)
 - and**
 2. Conditions
 - a. Hepatocellular carcinoma; **or**
 - b. Liver metastases from colorectal cancer; **or**
 - c. Functioning neuroendocrine tumors
 - and**
 3. Criteria
 - a. A poor candidate for surgical resection or unwilling to undergo surgical resection; **and**
 - b. Each lesion measures no more than 5 cm in diameter; **and**
 - c. No or minimal extra-hepatic metastases; **and**
 - d. All foci of disease are amenable to ablative therapy or surgical resection.

- B. Any of the following *arterially directed techniques* are considered **medically necessary** for individuals when *any* of the following conditions/criteria below have been met:
1. Techniques:
 - a. TACE*; **or**
 - b. TAE; **or**
 - c. SIRT/TARE

* For TACE using chemotherapy-loaded microspheres or immunoembolization, see the Not Medically Necessary section statement.

and

2. Conditions and Criteria:
 - a. Treatment for surgically unresectable primary hepatocellular carcinoma (HCC) when *all* of the following criteria are met:
 - i. Preserved liver function defined as Childs-Turcotte-Pugh Class A or B; **and**
 - ii. No or minimal extra-hepatic metastases;

Federal and State law, as well as contract language including definitions and specific coverage provisions/exclusions, and Medical Policy take precedence over Clinical UM Guidelines and must be considered first in determining eligibility for coverage. The member's contract benefits in effect on the date that services are rendered must be used. Clinical UM Guidelines, which address medical efficacy, should be considered before utilizing medical opinion in adjudication. Medical technology is constantly evolving, and we reserve the right to review and update Clinical UM Guidelines periodically. Clinical UM guidelines are used when the plan performs utilization review for the subject. Due to variances in utilization patterns, each plan may choose whether or not to adopt a particular Clinical UM Guideline. To determine if review is required for this Clinical UM Guideline, please contact the customer service number on the back of the member's card.

No part of this publication may be reproduced, stored in a retrieval system or transmitted, in any form or by any means, electronic, mechanical, photocopying, or otherwise, without permission from the health plan.

© CPT Only – American Medical Association

Healthy Blue is a Medicaid product offered by Missouri Care, Inc., a MO HealthNet Managed Care health plan contracting with the Missouri Department of Social Services. Healthy Blue is administered statewide by Missouri Care, Inc. and administered in the Kansas City service region by Missouri Care, Inc. in cooperation with Blue Cross and Blue Shield of Kansas City. Missouri Care, Inc. and Blue Cross and Blue Shield of Kansas City are both independent licensees of the Blue Cross and Blue Shield Association.

or

- b. Treatment for individuals with liver-only metastasis from uveal (ocular) melanoma; **or**
- c. Palliative treatment of symptoms associated with neuroendocrine (carcinoid or non-carcinoid) tumors; **or**
- d. Palliative treatment of liver-related symptoms due to tumor bulk (for example, pain) from a primary or metastatic tumor.

- C. SIRT/TARE is considered **medically necessary** as a secondary treatment of chemotherapy resistant or refractory colorectal cancer with liver dominant metastases.

II. *Bridge to Liver Transplantation*

- A. SIRT/TARE, TACE, TAE, PEI, RFA, or microwave ablation is considered **medically necessary** as a bridge to liver transplantation, when **all** of the following criteria are met:
 - 1. Preserved liver function defined as Childs-Turcotte-Pugh Class A or B; **and**
 - 2. Three or fewer encapsulated nodules and each nodule is less than or equal to 5 centimeters in diameter; **and**
 - 3. No evidence of extra-hepatic metastases; **and**
 - 4. No evidence of portal vein occlusion.

III. *Hepatocellular Carcinoma in Individuals Who May Become Eligible for Liver Transplantation (Downstaging)*

PEI, RFA, TACE, TAE, or SIRT/TARE is considered **medically necessary** for the treatment of an individual when **both** of the following criteria are met:

- A. May become eligible for liver transplantation except that the hepatic lesion(s) size is greater than 5 centimeters in maximal diameter; **and**
- B. It can be reasonably expected that treatment will result in tumor size reduction to less than or equal to 5 centimeters in maximal diameter.

Not Medically Necessary:

Histotripsy is considered **not medically necessary** for the treatment of primary and metastatic liver malignancies.

Locally ablative techniques are considered **not medically necessary** when the criteria above are not met.

Arterially directed techniques are considered **not medically necessary** when the criteria above are not met.

Federal and State law, as well as contract language including definitions and specific coverage provisions/exclusions, and Medical Policy take precedence over Clinical UM Guidelines and must be considered first in determining eligibility for coverage. The member's contract benefits in effect on the date that services are rendered must be used. Clinical UM Guidelines, which address medical efficacy, should be considered before utilizing medical opinion in adjudication. Medical technology is constantly evolving, and we reserve the right to review and update Clinical UM Guidelines periodically. Clinical UM guidelines are used when the plan performs utilization review for the subject. Due to variances in utilization patterns, each plan may choose whether or not to adopt a particular Clinical UM Guideline. To determine if review is required for this Clinical UM Guideline, please contact the customer service number on the back of the member's card.

No part of this publication may be reproduced, stored in a retrieval system or transmitted, in any form or by any means, electronic, mechanical, photocopying, or otherwise, without permission from the health plan.

© CPT Only – American Medical Association

Healthy Blue is a Medicaid product offered by Missouri Care, Inc., a MO HealthNet Managed Care health plan contracting with the Missouri Department of Social Services. Healthy Blue is administered statewide by Missouri Care, Inc. and administered in the Kansas City service region by Missouri Care, Inc. in cooperation with Blue Cross and Blue Shield of Kansas City. Missouri Care, Inc. and Blue Cross and Blue Shield of Kansas City are both independent licensees of the Blue Cross and Blue Shield Association.

Locoregional Techniques for Treating Primary and Metastatic Liver Malignancies

TACE using the following techniques are considered **not medically necessary** for any indication:

- A. Drug-eluting beads (DEB-TACE) (also known as drug-loaded microspheres); **or**
- B. Immunoembolization (for example, granulocyte-macrophage colony-stimulating factor [GM-CSF]).

Coding

The following codes for treatments and procedures applicable to this guideline are included below for informational purposes. Inclusion or exclusion of a procedure, diagnosis or device code(s) does not constitute or imply member coverage or provider reimbursement policy. Please refer to the member's contract benefits in effect at the time of service to determine coverage or non-coverage of these services as it applies to an individual member.

Ablative Techniques: Cryosurgical

When services may be Medically Necessary when criteria are met:

CPT

- 47371 Laparoscopy, surgical, ablation of 1 or more liver tumor(s); cryosurgical
- 47381 Ablation, open, of 1 or more liver tumor(s); cryosurgical
- 47383 Ablation, 1 or more liver tumor(s), percutaneous, cryoablation

ICD-10 Procedure

For the following codes **when specified as cryosurgical ablation:**

- 0F500ZZ-0F504ZZ Destruction of liver [by approach; includes codes 0F500ZZ, 0F503ZZ, 0F504ZZ]
- 0F510ZZ-0F514ZZ Destruction of right lobe liver [by approach; includes codes 0F510ZZ, 0F513ZZ, 0F514ZZ]
- 0F520ZZ-0F524ZZ Destruction of left lobe liver [by approach; includes codes 0F520ZZ, 0F523ZZ, 0F524ZZ]

ICD-10 Diagnosis

- C18.0-C18.9 Malignant neoplasm of colon
- C19 Malignant neoplasm of rectosigmoid junction
- C20 Malignant neoplasm of rectum
- C21.0-C21.8 Malignant neoplasm of anus and anal canal
- C22.0-C22.9 Malignant neoplasm of liver and intrahepatic bile ducts
- C25.4 Malignant neoplasm of endocrine pancreas
- C73 Malignant neoplasm of thyroid gland
- C74.00-C74.92 Malignant neoplasm of adrenal gland
- C75.0-C75.9 Malignant neoplasm of other endocrine glands and related structures
- C7A.00-C7A.8 Malignant neuroendocrine tumors

Federal and State law, as well as contract language including definitions and specific coverage provisions/exclusions, and Medical Policy take precedence over Clinical UM Guidelines and must be considered first in determining eligibility for coverage. The member's contract benefits in effect on the date that services are rendered must be used. Clinical UM Guidelines, which address medical efficacy, should be considered before utilizing medical opinion in adjudication. Medical technology is constantly evolving, and we reserve the right to review and update Clinical UM Guidelines periodically. Clinical UM guidelines are used when the plan performs utilization review for the subject. Due to variances in utilization patterns, each plan may choose whether or not to adopt a particular Clinical UM Guideline. To determine if review is required for this Clinical UM Guideline, please contact the customer service number on the back of the member's card.

No part of this publication may be reproduced, stored in a retrieval system or transmitted, in any form or by any means, electronic, mechanical, photocopying, or otherwise, without permission from the health plan.

© CPT Only – American Medical Association

Healthy Blue is a Medicaid product offered by Missouri Care, Inc., a MO HealthNet Managed Care health plan contracting with the Missouri Department of Social Services. Healthy Blue is administered statewide by Missouri Care, Inc. and administered in the Kansas City service region by Missouri Care, Inc. in cooperation with Blue Cross and Blue Shield of Kansas City. Missouri Care, Inc. and Blue Cross and Blue Shield of Kansas City are both independent licensees of the Blue Cross and Blue Shield Association.

Locoregional Techniques for Treating Primary and Metastatic Liver Malignancies

C7B.00-C7B.8	Secondary neuroendocrine tumors
C78.7	Secondary malignant neoplasm of liver and intrahepatic bile duct
D01.5	Carcinoma in situ of liver, gallbladder and bile ducts
E34.0	Carcinoid syndrome

When services are Not Medically Necessary:

For the procedure and diagnosis codes listed above when criteria are not met or for situations designated in the Clinical Indications section as not medically necessary.

Ablative Techniques: Radiofrequency, Microwave, Percutaneous Ethanol Injection

When services may be Medically Necessary when criteria are met:

CPT

47370	Laparoscopy, surgical, ablation of 1 or more liver tumor(s); radiofrequency
47380	Ablation, open, of 1 or more liver tumor(s); radiofrequency
47382	Ablation, 1 or more liver tumor(s), percutaneous, radiofrequency
47399	Unlisted procedure, liver [when specified as microwave ablation or percutaneous ethanol injection]

ICD-10 Procedure

	For the following codes when specified as PEI, RFA or microwave ablation:
0F500ZZ-0F504ZZ	Destruction of liver [by approach; includes codes 0F500ZZ, 0F503ZZ, 0F504ZZ]
0F510ZZ-0F514ZZ	Destruction of right lobe liver [by approach; includes codes 0F510ZZ, 0F513ZZ, 0F514ZZ]
0F520ZZ-0F524ZZ	Destruction of left lobe liver [by approach; includes codes 0F520ZZ, 0F523ZZ, 0F524ZZ]

ICD-10 Diagnosis

C18.0-C18.9	Malignant neoplasm of colon
C19	Malignant neoplasm of rectosigmoid junction
C20	Malignant neoplasm of rectum
C21.0-C21.8	Malignant neoplasm of anus and anal canal
C22.0-C22.9	Malignant neoplasm of liver and intrahepatic bile ducts
C25.4	Malignant neoplasm of endocrine pancreas
C73	Malignant neoplasm of thyroid gland
C74.00-C74.92	Malignant neoplasm of adrenal gland
C75.0-C75.9	Malignant neoplasm of other endocrine glands and related structures
C7A.00-C7A.8	Malignant neuroendocrine tumors

Federal and State law, as well as contract language including definitions and specific coverage provisions/exclusions, and Medical Policy take precedence over Clinical UM Guidelines and must be considered first in determining eligibility for coverage. The member's contract benefits in effect on the date that services are rendered must be used. Clinical UM Guidelines, which address medical efficacy, should be considered before utilizing medical opinion in adjudication. Medical technology is constantly evolving, and we reserve the right to review and update Clinical UM Guidelines periodically. Clinical UM guidelines are used when the plan performs utilization review for the subject. Due to variances in utilization patterns, each plan may choose whether or not to adopt a particular Clinical UM Guideline. To determine if review is required for this Clinical UM Guideline, please contact the customer service number on the back of the member's card.

No part of this publication may be reproduced, stored in a retrieval system or transmitted, in any form or by any means, electronic, mechanical, photocopying, or otherwise, without permission from the health plan.

© CPT Only – American Medical Association

Healthy Blue is a Medicaid product offered by Missouri Care, Inc., a MO HealthNet Managed Care health plan contracting with the Missouri Department of Social Services. Healthy Blue is administered statewide by Missouri Care, Inc. and administered in the Kansas City service region by Missouri Care, Inc. in cooperation with Blue Cross and Blue Shield of Kansas City. Missouri Care, Inc. and Blue Cross and Blue Shield of Kansas City are both independent licensees of the Blue Cross and Blue Shield Association.

Locoregional Techniques for Treating Primary and Metastatic Liver Malignancies

C7B.00-C7B.8	Secondary neuroendocrine tumors
C78.7	Secondary malignant neoplasm of liver and intrahepatic bile duct
D01.5	Carcinoma in situ of liver, gallbladder and bile ducts
E34.0	Carcinoid syndrome
Z76.82	Awaiting organ transplant status

When services are Not Medically Necessary:

For the procedure and diagnosis codes listed above when criteria are not met.

TACE or TAE

When services may be Medically Necessary when criteria are met:

CPT

For the following CPT and ICD-10 Procedure codes **when specified as TACE or TAE not using drug-loaded microspheres or drug-eluting beads, or an immunologic agent**]:

37243	Vascular embolization or occlusion, inclusive of all radiological supervision and interpretation, intraprocedural roadmapping, and imaging guidance necessary to complete the intervention; for tumors, organ ischemia, or infarction [<i>when specified as TAE, or TACE not using drug-loaded microspheres or drug-eluting beads or an immunologic agent</i>]
-------	--

ICD-10 Procedure

04L33DZ	Occlusion of hepatic artery with intraluminal device, percutaneous approach [<i>when specified as TAE, or TACE not using drug-loaded microspheres or drug-eluting beads or an immunologic agent</i>]
04L33ZZ	Occlusion of hepatic artery, percutaneous approach [<i>when specified as TAE, or TACE not using drug-loaded microspheres or drug-eluting beads or an immunologic agent</i>]

ICD-10 Diagnosis

C22.0-C22.9	Malignant neoplasm of liver and intrahepatic bile ducts
C25.4	Malignant neoplasm of endocrine pancreas
C69.30-C69.32	Malignant neoplasm of choroid
C69.40-C69.42	Malignant neoplasm of ciliary body
C73	Malignant neoplasm of thyroid
C74.00-C74.92	Malignant neoplasm of adrenal gland
C75.0-C75.9	Malignant neoplasm of other endocrine glands and related structures
C78.7	Secondary malignant neoplasm of liver and intrahepatic bile duct

Federal and State law, as well as contract language including definitions and specific coverage provisions/exclusions, and Medical Policy take precedence over Clinical UM Guidelines and must be considered first in determining eligibility for coverage. The member's contract benefits in effect on the date that services are rendered must be used. Clinical UM Guidelines, which address medical efficacy, should be considered before utilizing medical opinion in adjudication. Medical technology is constantly evolving, and we reserve the right to review and update Clinical UM Guidelines periodically. Clinical UM guidelines are used when the plan performs utilization review for the subject. Due to variances in utilization patterns, each plan may choose whether or not to adopt a particular Clinical UM Guideline. To determine if review is required for this Clinical UM Guideline, please contact the customer service number on the back of the member's card.

No part of this publication may be reproduced, stored in a retrieval system or transmitted, in any form or by any means, electronic, mechanical, photocopying, or otherwise, without permission from the health plan.

© CPT Only – American Medical Association

Healthy Blue is a Medicaid product offered by Missouri Care, Inc., a MO HealthNet Managed Care health plan contracting with the Missouri Department of Social Services. Healthy Blue is administered statewide by Missouri Care, Inc. and administered in the Kansas City service region by Missouri Care, Inc. in cooperation with Blue Cross and Blue Shield of Kansas City. Missouri Care, Inc. and Blue Cross and Blue Shield of Kansas City are both independent licensees of the Blue Cross and Blue Shield Association.

Locoregional Techniques for Treating Primary and Metastatic Liver Malignancies

C7A.00-C7A.8	Malignant neuroendocrine tumors
C7B.02	Secondary carcinoid tumors of liver
D01.5	Carcinoma in situ of liver, gallbladder and bile ducts
E16.0-E16.2	Drug-induced, other and unspecified hypoglycemia
E16.4	Increased secretion of gastrin (Zollinger-Ellison syndrome)
E34.0	Carcinoid syndrome
Z76.82	Awaiting organ transplant status

For the following diagnosis code range for palliation of liver metastases:

C00.0-C80.2	Malignant neoplasms
-------------	---------------------

When services are Not Medically Necessary:

For the procedure and diagnosis codes listed above when criteria are not met.

SIRT/TARE

When services may be Medically Necessary when criteria are met:

For the following codes **when specified as SIRT/TARE radioembolization using yttrium-90 microspheres:**

CPT

37243	Vascular embolization or occlusion, inclusive of all radiological supervision and interpretation, intraprocedural roadmapping, and imaging guidance necessary to complete the intervention; for tumors, organ ischemia, or infarction [when specified as radioembolization using yttrium-90 microspheres]
79445	Radiopharmaceutical therapy, by intra-arterial particulate administration [when specified as transcatheter tumor destruction procedure using yttrium-90 microspheres]

HCPCS

C2616	Brachytherapy source, nonstranded, yttrium-90, per source [when specified as yttrium-90 microspheres]
S2095	Transcatheter occlusion or embolization for tumor destruction, percutaneous, any method, using yttrium-90 microspheres

ICD-10 Procedure

3E053HZ	Introduction of radioactive substance into peripheral artery, percutaneous approach [when specified as SIRT/TARE using yttrium-90 microspheres]
---------	---

ICD-10 Diagnosis

Federal and State law, as well as contract language including definitions and specific coverage provisions/exclusions, and Medical Policy take precedence over Clinical UM Guidelines and must be considered first in determining eligibility for coverage. The member's contract benefits in effect on the date that services are rendered must be used. Clinical UM Guidelines, which address medical efficacy, should be considered before utilizing medical opinion in adjudication. Medical technology is constantly evolving, and we reserve the right to review and update Clinical UM Guidelines periodically. Clinical UM guidelines are used when the plan performs utilization review for the subject. Due to variances in utilization patterns, each plan may choose whether or not to adopt a particular Clinical UM Guideline. To determine if review is required for this Clinical UM Guideline, please contact the customer service number on the back of the member's card.

No part of this publication may be reproduced, stored in a retrieval system or transmitted, in any form or by any means, electronic, mechanical, photocopying, or otherwise, without permission from the health plan.

© CPT Only – American Medical Association

Healthy Blue is a Medicaid product offered by Missouri Care, Inc., a MO HealthNet Managed Care health plan contracting with the Missouri Department of Social Services. Healthy Blue is administered statewide by Missouri Care, Inc. and administered in the Kansas City service region by Missouri Care, Inc. in cooperation with Blue Cross and Blue Shield of Kansas City. Missouri Care, Inc. and Blue Cross and Blue Shield of Kansas City are both independent licensees of the Blue Cross and Blue Shield Association.

Locoregional Techniques for Treating Primary and Metastatic Liver Malignancies

C18.0-C18.9	Malignant neoplasm of colon
C19	Malignant neoplasm of rectosigmoid junction
C20	Malignant neoplasm of rectum
C21.0-C21.8	Malignant neoplasm of anus and anal canal
C22.0-C22.9	Malignant neoplasm of liver and intrahepatic bile ducts
C25.4	Malignant neoplasm of endocrine pancreas
C69.30-C69.32	Malignant neoplasm of choroid
C69.40-C69.42	Malignant neoplasm of ciliary body
C73	Malignant neoplasm of thyroid
C74.00-C74.92	Malignant neoplasm of adrenal gland
C75.0-C75.9	Malignant neoplasm of other endocrine glands and related structures
C78.7	Secondary malignant neoplasm of liver and intrahepatic bile duct
C7A.00-C7A.8	Malignant neuroendocrine tumors
C7B.02	Secondary carcinoid tumors of liver
D01.5	Carcinoma in situ of liver, gallbladder and bile ducts
E16.0-E16.2	Drug-induced, other and unspecified hypoglycemia
E16.4	Increased secretion of gastrin (Zollinger-Ellison syndrome)
E34.0	Carcinoid syndrome
Z76.82	Awaiting organ transplant status

For the following diagnosis code ranges for palliation of liver metastases:

C00.0-C80.2	Malignant neoplasms
-------------	---------------------

When services are Not Medically Necessary:

For the procedure and diagnosis codes listed above when criteria are not met.

When services are also Not Medically Necessary:

CPT

37243	Vascular embolization or occlusion, inclusive of all radiological supervision and interpretation, intraprocedural roadmapping, and imaging guidance necessary to complete the intervention; for tumors, organ ischemia, or infarction [when specified as TAE, or TACE using drug-loaded microspheres or drug-eluting beads or an immunologic agent (immunoembolization)]
0686T	Histotripsy (ie, non-thermal ablation via acoustic energy delivery) of malignant hepatocellular tissue, including image guidance

HCPCS

Federal and State law, as well as contract language including definitions and specific coverage provisions/exclusions, and Medical Policy take precedence over Clinical UM Guidelines and must be considered first in determining eligibility for coverage. The member's contract benefits in effect on the date that services are rendered must be used. Clinical UM Guidelines, which address medical efficacy, should be considered before utilizing medical opinion in adjudication. Medical technology is constantly evolving, and we reserve the right to review and update Clinical UM Guidelines periodically. Clinical UM guidelines are used when the plan performs utilization review for the subject. Due to variances in utilization patterns, each plan may choose whether or not to adopt a particular Clinical UM Guideline. To determine if review is required for this Clinical UM Guideline, please contact the customer service number on the back of the member's card.

No part of this publication may be reproduced, stored in a retrieval system or transmitted, in any form or by any means, electronic, mechanical, photocopying, or otherwise, without permission from the health plan.

© CPT Only – American Medical Association

Healthy Blue is a Medicaid product offered by Missouri Care, Inc., a MO HealthNet Managed Care health plan contracting with the Missouri Department of Social Services. Healthy Blue is administered statewide by Missouri Care, Inc. and administered in the Kansas City service region by Missouri Care, Inc. in cooperation with Blue Cross and Blue Shield of Kansas City. Missouri Care, Inc. and Blue Cross and Blue Shield of Kansas City are both independent licensees of the Blue Cross and Blue Shield Association.

C9790	Histotripsy (ie, non-thermal ablation via acoustic energy delivery) of malignant renal tissue, including image guidance
ICD-10 Procedure	
04L33DZ	Occlusion of hepatic artery with intraluminal device, percutaneous approach [when specified as TAE, or TACE using drug-loaded microspheres or drug-eluting beads or an immunologic agent (immunoembolization)]
04L33ZZ	Occlusion of hepatic artery, percutaneous approach [when specified as TAE, or TACE using drug-loaded microspheres or drug-eluting beads or an immunologic agent (immunoembolization)]
ICD-10 Diagnosis	
C00.0-C96.9	Malignant neoplasms
D01.5	Carcinoma in situ of liver, gallbladder and bile ducts
E34.0	Carcinoid syndrome

Discussion/General Information

Description and Prevalence of Disease

According to the American Cancer Institute (ACS), there will be an estimated 41,210 new cases of primary liver cancer and intrahepatic bile duct cancer diagnosed in the United States (U.S.) in 2023 and approximately 29,380 deaths associated with the disease. Since 1980, the incidence of hepatic cancer has more than tripled and the increasing incidence attributed to high rates of hepatitis C (HCV), nonalcoholic fatty liver disease (NAFLD), and metabolic syndrome (Heimbach, 2017).

Primary hepatocellular carcinoma (HCC) pertains to malignancies arising from the liver, while hepatobiliary cancers originate from bile ducts and/or gallbladder. These groups of malignancies are collectively known as intrahepatic and extrahepatic cholangiocarcinoma. Hepatic carcinoma can arise either as primary liver cancer or by metastasis to the liver from other tissue origins. Malignancies of the liver are comprised primarily of adenocarcinomas classified by hepatocellular and cholangiocarcinoma cell types (National Cancer Institute [NCI], 2023). Hepatocellular carcinoma is the most common form of hepatic malignancies and makes up 90% of the cases. Gallbladder cancer is the most common type of biliary tract malignancies. Cholangiocarcinoma occurs throughout the biliary tree (National Comprehensive Cancer Network® [NCCN], V1.2023).

Neuroendocrine tumors may also involve the liver, where hormone production can cause systemic symptoms. The most common neuroendocrine tumor is the carcinoid tumor where excessive hormone production is associated with

Federal and State law, as well as contract language including definitions and specific coverage provisions/exclusions, and Medical Policy take precedence over Clinical UM Guidelines and must be considered first in determining eligibility for coverage. The member's contract benefits in effect on the date that services are rendered must be used. Clinical UM Guidelines, which address medical efficacy, should be considered before utilizing medical opinion in adjudication. Medical technology is constantly evolving, and we reserve the right to review and update Clinical UM Guidelines periodically. Clinical UM guidelines are used when the plan performs utilization review for the subject. Due to variances in utilization patterns, each plan may choose whether or not to adopt a particular Clinical UM Guideline. To determine if review is required for this Clinical UM Guideline, please contact the customer service number on the back of the member's card.

No part of this publication may be reproduced, stored in a retrieval system or transmitted, in any form or by any means, electronic, mechanical, photocopying, or otherwise, without permission from the health plan.

© CPT Only – American Medical Association

Healthy Blue is a Medicaid product offered by Missouri Care, Inc., a MO HealthNet Managed Care health plan contracting with the Missouri Department of Social Services. Healthy Blue is administered statewide by Missouri Care, Inc. and administered in the Kansas City service region by Missouri Care, Inc. in cooperation with Blue Cross and Blue Shield of Kansas City. Missouri Care, Inc. and Blue Cross and Blue Shield of Kansas City are both independent licensees of the Blue Cross and Blue Shield Association.

the carcinoid syndrome, characterized by debilitating flushing, wheezing and diarrhea. Pancreatic endocrine tumors that produce gastrin, insulin or other pancreatic hormones are unusual types of neuroendocrine tumors. Pancreatic endocrine (i.e., islet cell) tumors differ from the more common pancreatic epithelial tumors that arise from the exocrine portion of the pancreas. Surgical resection is typically not possible for neuroendocrine tumors, and treatment tends to focus on palliation of specific systemic symptoms.

There is no universal staging system utilized by all facilities within the US. In addition, the potential presence of an underlying liver disease complicates the treatment of HCC (NCCN, V1.2023). More than 80% of the individuals diagnosed with HCC are found to have pre-existing cirrhosis (Marrero, 2018).

Extrahepatic Disease

At initial diagnosis, extrahepatic metastases are detected in 13-36% of HCC cases. At autopsy, approximately 68% of cases are found to have extrahepatic disease, imaging is underestimating the extent of disease or metastases are developing during or following treatment. Post-instrumentation seeding of HCC can occur following biopsies or percutaneous ablation. Also, tumors may rupture or slough off cells during arterially directed therapies, resulting in extrahepatic spread (Arora, 2021). There is no specific definition of oligometastatic disease, but for this guideline it is defined as up to 5 lesions extrahepatic lesions (Lievens, 2020).

Liver metastases can develop from any type of cancer, but metastases from colorectal cancer (CRC) are the most common. Metastases develop in approximately 50-60% of those diagnosed with CRC and 80-90% of those individuals present with unresectable metastatic liver disease. Stewart and associates (2018) analyzed survival times and palliation in those with CRC metastases. The median survival of individuals with unresectable metastases to the liver is 13 months. The median survival of individuals with extrahepatic metastases ranges from a low of 19 months in bone metastases to 36 months in brain metastases. Metastases to the liver largely determine the length of survival in CRC. Over 70% of individuals with unresectable liver metastatic disease will die from liver metastases. The authors note the following for individuals with CRC metastases:

Disease specific survival is also significantly shorter for those who die of liver metastasis, compared to patients who die from other metastatic sites. Thus, addressing liver metastases initially is the most clinically relevant, since this is the most life limiting. Currently, patients who do not undergo surgical treatment of liver metastases typically live less than 18 months, with no 5-year survivors. By comparison, those who are resected but recur have a median survival of 40 months, and have a 17% 5-year survival. As such, liver directed therapies shift the cause of death to other sites at a later time point. For this reason, having metastases at other sites does not change survival for patients with liver metastases, as long as they are candidates for surgery.

Federal and State law, as well as contract language including definitions and specific coverage provisions/exclusions, and Medical Policy take precedence over Clinical UM Guidelines and must be considered first in determining eligibility for coverage. The member's contract benefits in effect on the date that services are rendered must be used. Clinical UM Guidelines, which address medical efficacy, should be considered before utilizing medical opinion in adjudication. Medical technology is constantly evolving, and we reserve the right to review and update Clinical UM Guidelines periodically. Clinical UM guidelines are used when the plan performs utilization review for the subject. Due to variances in utilization patterns, each plan may choose whether or not to adopt a particular Clinical UM Guideline. To determine if review is required for this Clinical UM Guideline, please contact the customer service number on the back of the member's card.

No part of this publication may be reproduced, stored in a retrieval system or transmitted, in any form or by any means, electronic, mechanical, photocopying, or otherwise, without permission from the health plan.

© CPT Only – American Medical Association

Healthy Blue is a Medicaid product offered by Missouri Care, Inc., a MO HealthNet Managed Care health plan contracting with the Missouri Department of Social Services. Healthy Blue is administered statewide by Missouri Care, Inc. and administered in the Kansas City service region by Missouri Care, Inc. in cooperation with Blue Cross and Blue Shield of Kansas City. Missouri Care, Inc. and Blue Cross and Blue Shield of Kansas City are both independent licensees of the Blue Cross and Blue Shield Association.

Locoregional Techniques for Treating Primary and Metastatic Liver Malignancies

The NCCN clinical practice guideline (CPG) for HCC (V1.2023) includes both ablation techniques and arterially directed therapies as options for HCC with minimal or uncertain extrahepatic, if surgery is not an option. While early reports indicated that the use of locoregional techniques in individuals with extrahepatic are associated with poorer prognostic outcomes (Wong, 2009), locoregional techniques appear to provide improved survival times in individuals with extrahepatic metastasis when hepatic lesions are treated.

Ablative Techniques (Cryoablation, RFA, MWA or PEI)

Local ablative therapy for hepatic metastasis is generally indicated when there is no extrahepatic disease or when all sites of disease can be treated, criteria that predominantly apply to individuals with colorectal carcinoma or certain neuroendocrine malignancies. Currently, surgical resection with adequate margins or liver transplantation are considered the treatments of choice and are viewed as potentially curative. Ablative therapy may be considered as a curative therapy in individuals with small lesions (NCCN, V1.2023). Ablative therapy may also be an option for individuals who are not candidates for surgical resection due to the location or tumor load, inadequate liver reserve or comorbid conditions. Common complications of ablative therapies include abscess formation, infection, hemorrhage and injury to adjacent anatomical organs. There have also been reports of death associated with the ablative procedures.

Cryosurgery, also called cryotherapy or cryoablation, is the use of extreme cold to destroy abnormal tissue. Cryosurgical ablation is performed by inserting a cryoprobe into the lesion followed by injection of a coolant such as liquid nitrogen or argon gas, freezing and killing the surrounding tissue. The dead tissue is then naturally absorbed by the body. Cryosurgery does have side effects; however, they may be less severe than those associated with conventional surgery or radiation therapy.

Radiofrequency ablation (RFA) involves inserting a probe into the center of the tumor to deliver an alternating electric current causing an increase in temperature and coagulative necrosis of the cell and death. RFA can be performed as an open surgical procedure, laparoscopically, or percutaneously with ultrasound or computed tomography (CT) guidance. The NCCN CPG for HCC (V1.2023) notes that although individuals with HCC should first be considered for surgical curative therapy, RFA may be considered a potential curative therapy in select individuals in early-stage disease who are not surgical candidates.

Microwave ablation (MWA) is a form of thermal ablation, along with cryoablation and RFA, in which probes, inserted into the tumor, deliver microwave energy that heats and kills surrounding tissue. One purported advantage of MWA over RFA is the ability to achieve higher temperatures and obtain a larger ablation zone (Abdelaziz, 2015; Veltri, 2015). For this reason, MWA has generated some interest as a potential therapy for larger lesions although the evidence does not currently support that use.

Federal and State law, as well as contract language including definitions and specific coverage provisions/exclusions, and Medical Policy take precedence over Clinical UM Guidelines and must be considered first in determining eligibility for coverage. The member's contract benefits in effect on the date that services are rendered must be used. Clinical UM Guidelines, which address medical efficacy, should be considered before utilizing medical opinion in adjudication. Medical technology is constantly evolving, and we reserve the right to review and update Clinical UM Guidelines periodically. Clinical UM guidelines are used when the plan performs utilization review for the subject. Due to variances in utilization patterns, each plan may choose whether or not to adopt a particular Clinical UM Guideline. To determine if review is required for this Clinical UM Guideline, please contact the customer service number on the back of the member's card.

No part of this publication may be reproduced, stored in a retrieval system or transmitted, in any form or by any means, electronic, mechanical, photocopying, or otherwise, without permission from the health plan.

© CPT Only – American Medical Association

Healthy Blue is a Medicaid product offered by Missouri Care, Inc., a MO HealthNet Managed Care health plan contracting with the Missouri Department of Social Services. Healthy Blue is administered statewide by Missouri Care, Inc. and administered in the Kansas City service region by Missouri Care, Inc. in cooperation with Blue Cross and Blue Shield of Kansas City. Missouri Care, Inc. and Blue Cross and Blue Shield of Kansas City are both independent licensees of the Blue Cross and Blue Shield Association.

Locoregional Techniques for Treating Primary and Metastatic Liver Malignancies

Percutaneous ethanol injection uses the injection of ethanol directly into tumor tissue, where it destroys the tumor tissue due to its dehydrative and protein degenerative effects. The relative hypervascularity of HCC ensures good penetration of the tumor with minimal spillover of ethanol into normal liver tissue.

The NCCN CPG for HCC (V1.2023) states the following with Category 2A recommendations in the Principles of Locoregional Therapy-Ablation section:

- Locoregional therapy should be considered in patients who are not candidates for surgical curative treatments, or as a part of a strategy to bridge patients for other curative therapies.
- All tumors should be amenable to ablation such that the tumor and, in the case of thermal ablation, a margin of normal tissue is treated. A margin is not expected following percutaneous ethanol injection.
- Tumors should be in a location accessible for percutaneous/laparoscopic/open approaches for ablation.
- Caution should be exercised when ablating lesions near major vessels, major bile ducts, diaphragm and other intra-abdominal organs.
- Ablation alone may be curative in treating tumors less than or equal to 3 cm. In well-selected patients with small properly located tumors, ablation should be considered as definitive treatment in the context of a multidisciplinary review. Lesions 3 to 5 cm may be treated to prolong survival using arterially directed therapies, or with combination of an arterially directed therapy and ablation as long as tumor location is accessible for ablation. Unresectable/inoperable lesions greater than 5 cm should be considered for treatment using arterially directed therapy, systemic therapy, or EBRT.

The AASLD practice guideline (Marrero, 2018) for HCC notes that ablation is the best treatment option for individuals with early-stage HCC who are not suitable for resection or liver transplantation. The modalities to achieve destruction of the malignant cells include RFA, microwave, PEI, and cryotherapy. The most effective treatment is generally dependent on size and location of lesions. RFA has been shown to be more effective than PEI in lesions between 2 and 4 cm (Peng, 2013; Tovoli, 2016). However, in cases in which RFA is contraindicated, (for example, near to the main biliary tree, abdominal organs, or heart) PEI could be an acceptable option.

In a position statement for the Society of Interventional Radiology (SIR), Gervais and colleagues (2009) noted “HCCs 5 cm or less in diameter have a higher probability of having complete ablation compared to those greater than 5 cm in diameter.” The authors also noted superior results with tumors smaller than 3 cm, acceptable (intermediate) results with tumors 3 to 5 cm, and “fairly dismal results for tumors larger than 5 cm.”

Feng and colleagues (2015) conducted a meta-analysis to compare percutaneous RFA and surgical resection as treatments of small HCC. A total of 15,482 individuals from 3 randomized controlled trials (RCTs) and 20 retrospective studies were included in the efficacy and safety analysis. There were 7524 individuals treated with surgical resection of the liver, and 7958 treated with RFA. At 1, 3 and 5 years, surgical resection had higher OS and

Federal and State law, as well as contract language including definitions and specific coverage provisions/exclusions, and Medical Policy take precedence over Clinical UM Guidelines and must be considered first in determining eligibility for coverage. The member's contract benefits in effect on the date that services are rendered must be used. Clinical UM Guidelines, which address medical efficacy, should be considered before utilizing medical opinion in adjudication. Medical technology is constantly evolving, and we reserve the right to review and update Clinical UM Guidelines periodically. Clinical UM guidelines are used when the plan performs utilization review for the subject. Due to variances in utilization patterns, each plan may choose whether or not to adopt a particular Clinical UM Guideline. To determine if review is required for this Clinical UM Guideline, please contact the customer service number on the back of the member's card.

No part of this publication may be reproduced, stored in a retrieval system or transmitted, in any form or by any means, electronic, mechanical, photocopying, or otherwise, without permission from the health plan.

© CPT Only – American Medical Association

Healthy Blue is a Medicaid product offered by Missouri Care, Inc., a MO HealthNet Managed Care health plan contracting with the Missouri Department of Social Services. Healthy Blue is administered statewide by Missouri Care, Inc. and administered in the Kansas City service region by Missouri Care, Inc. in cooperation with Blue Cross and Blue Shield of Kansas City. Missouri Care, Inc. and Blue Cross and Blue Shield of Kansas City are both independent licensees of the Blue Cross and Blue Shield Association.

recurrence-free rates compared to RFA. There was no difference in mortality between the two groups, but the RFA group had a significantly lower morbidity rate compared to the surgical resection group.

Chong and associates (2020) compared the safety and efficacy outcomes of RFA and MWA in individuals with unresectable HCC (n=93) in a prospective randomized study. Participation was limited to those with lesions 3 or less, a maximum tumor diameter of 5 cm or less and an absence of extrahepatic metastasis. Participants were randomized to receive either RFA (n=46) or MWA (n=47). The MWA versus RFA 1-year, 3-year, 5-year OS rates were 97.9%, 67.1%, 42.8% and 93.5%, 72.7% and 56.7% respectively (p=0.899). There were no cases of treatment related mortality at 30 days. The authors concluded that both procedures were equally safe and effective in treating small HCC. MWA did show shorter ablation times and no risk of burn injury. Other studies support the finding that MWA and RFA therapy produce similar clinical outcomes in a comparable population (Kamal, 2019; Vietti Violi, 2018; Yu, 2017; Zhang, 2008).

In a systematic review, Shen and associates (2013) assessed clinical outcomes of each therapy, including survival, recurrence and major complications in individuals with HCC lesions less than 3 cm. While RFA was shown to have a higher 3-year OS rate and a lower rate of local recurrence, there was no difference between the therapies in terms of distant intrahepatic recurrence. RFA was associated with a higher rate of complications. RFA and PEI appear to have similar outcomes in individuals with early HCC (three or less lesions which are 5 cm or smaller) (Ikeda, 2001; Giorgio, 2011; Lencioni, 2003; Livraghi, 1999). Response to the initial treatment appears to be a significant predictor in survival rather than the type of ablation therapy (RFA versus PEI) used (Morimoto, 2007). Other studies evaluating PEI therapy have shown that hepatic function, Child-Pugh classification, and tumor size affect survival rates and individuals with tumors 3 cm or less with improved survival rates compared to larger tumors (Bruix, 2005; Lermite, 2006; Luo, 2005; Taniguchi, 2008).

Lencioni and colleagues (2003) published a randomized comparison of RFA and PEI in 102 individuals with hepatocellular cancer. Tumors were fully ablated in 91% of the participants treated with RFA and 85% of the individuals treated with PEI; however, an average of 5.4 sessions were required for PEI versus 1.1 for RFA. Additionally, there was a significant difference in the local recurrence-free survival rate at 1 year of 83% and 62% at 2 years for the PEI group. In comparison, the RFA group had a local recurrence-free survival rate at 1 year of 96% and 95% at 2 years. The overall 2-year survival was similar in both groups. Additional nonrandomized comparative studies reporting survival data also support the equivalency of these two options (Ikeda, 2001; Livraghi, 1999).

In a study of 153 enrolled individuals with newly diagnosed HCC, Morimoto and colleagues (2007) described two cohorts of participants. A total of 110 individuals received RFA ablation while 43 participants received PEI. Of those, 102 participants had single HCC tumors and 51 participants had two or three HCC nodules with a maximum diameter of 5 cm or less. The OS at 3 years was 75% and 59% at 5 years. No local tumor growth at 6 months following initial treatment was reported in 125 (82%) individuals. Twenty-eight (18%) participants had residual

Federal and State law, as well as contract language including definitions and specific coverage provisions/exclusions, and Medical Policy take precedence over Clinical UM Guidelines and must be considered first in determining eligibility for coverage. The member's contract benefits in effect on the date that services are rendered must be used. Clinical UM Guidelines, which address medical efficacy, should be considered before utilizing medical opinion in adjudication. Medical technology is constantly evolving, and we reserve the right to review and update Clinical UM Guidelines periodically. Clinical UM guidelines are used when the plan performs utilization review for the subject. Due to variances in utilization patterns, each plan may choose whether or not to adopt a particular Clinical UM Guideline. To determine if review is required for this Clinical UM Guideline, please contact the customer service number on the back of the member's card.

No part of this publication may be reproduced, stored in a retrieval system or transmitted, in any form or by any means, electronic, mechanical, photocopying, or otherwise, without permission from the health plan.

© CPT Only – American Medical Association

Healthy Blue is a Medicaid product offered by Missouri Care, Inc., a MO HealthNet Managed Care health plan contracting with the Missouri Department of Social Services. Healthy Blue is administered statewide by Missouri Care, Inc. and administered in the Kansas City service region by Missouri Care, Inc. in cooperation with Blue Cross and Blue Shield of Kansas City. Missouri Care, Inc. and Blue Cross and Blue Shield of Kansas City are both independent licensees of the Blue Cross and Blue Shield Association.

Locoregional Techniques for Treating Primary and Metastatic Liver Malignancies

tumor and were retreated. There was no significant difference in successful initial treatment outcomes between the treatment modalities; 90 (82%) of the 110 individuals treated with RFA, and 35 (81%) of 43 individuals treated with PEI, had no residual tumor by contrast enhanced computerized tomography (CT) at 6 months. Median follow-up of 34 months revealed 58 (53%) of 110 individuals treated with RFA and 25 (58%) of 43 individuals treated with PEI had tumor recurrence. Twenty-three participants died and 3 participants were lost to follow-up. Tumor size was one of the pre-treatment factors associated with survival. Overall, the significant predictor of survival was the response to initial treatment.

The current RFA devices are capable of producing a lesion of 5 cm or more in one session. This is sufficient to allow for the full ablation of a 3cm tumor with adequate margins (Peng, 2013; Tovoli, 2016). Ablation of larger tumors was more technically challenging as overlapping fields were required to ensure adequate ablation. Radiographic studies present challenges when used to accurately determine the defining margins for overlap. There have been several prospective or retrospective studies have shown some promising results in the treatment of larger lesions with locoregional therapies such as MWA or RFA (Abdelaziz, 2015; Dai, 2015; Veltri, 2015). However, at this time, the use of ablative therapies have not been shown in studies to be clinically appropriate in the treatment tumors larger than 5 cm.

Neuroendocrine tumors with a high incidence of distant metastases frequently involve the liver (Bacchetti, 2013). Treatment of neuroendocrine cancers is primarily palliative in nature, to reduce levels of functioning hormones, which may result in significant morbidity. There is considerable literature regarding the use of ablative techniques, which support an increase in survival times when compared to conservative treatment in select individuals or to reduce levels of functioning hormones (Adam, 2002; Bacchetti, 2013; Henn, 2003; Saxena, 2012). Overall, the studies do not show that a specific ablative technique is superior. While RFA appears to be the most common modality used in this country, the choice of ablative technique is often based on individual physician and institution experience and preference. Locally ablative techniques are frequently used with resective surgery.

Retrospective studies and case series using a locally ablative technique to treat liver metastases from primaries other than colorectal and neuroendocrine tumors generally report the feasibility of the procedure and suggest improved progression-free survival (Bleicher, 2003; Fairhurst, 2016; Kümler, 2015; Seidensticker, 2015; Xiao, 2018).). However, because of the limited data and heterogeneous clinical presentations, optimal selection criteria have not been identified and uniformly adopted. Various authors noted prospective trials are needed to confirm the results. Recommendations for routine local ablation of hepatic metastases are included in the NCCN CPGs for colorectal cancer and neuroendocrine cancers. However, the treatments are not recommended for other metastatic tumors to the liver.

In a retrospective review of 110 individuals, Shady and colleagues (2018) compared the local tumor progression free survival (LTPFS) in individuals who underwent either RFA or MWA to treat colorectal liver metastases. A total of 62 individuals with 85 tumors underwent RFA in 72 sessions, and 48 individuals with 60 tumors underwent

Federal and State law, as well as contract language including definitions and specific coverage provisions/exclusions, and Medical Policy take precedence over Clinical UM Guidelines and must be considered first in determining eligibility for coverage. The member's contract benefits in effect on the date that services are rendered must be used. Clinical UM Guidelines, which address medical efficacy, should be considered before utilizing medical opinion in adjudication. Medical technology is constantly evolving, and we reserve the right to review and update Clinical UM Guidelines periodically. Clinical UM guidelines are used when the plan performs utilization review for the subject. Due to variances in utilization patterns, each plan may choose whether or not to adopt a particular Clinical UM Guideline. To determine if review is required for this Clinical UM Guideline, please contact the customer service number on the back of the member's card.

No part of this publication may be reproduced, stored in a retrieval system or transmitted, in any form or by any means, electronic, mechanical, photocopying, or otherwise, without permission from the health plan.

© CPT Only – American Medical Association

Healthy Blue is a Medicaid product offered by Missouri Care, Inc., a MO HealthNet Managed Care health plan contracting with the Missouri Department of Social Services. Healthy Blue is administered statewide by Missouri Care, Inc. and administered in the Kansas City service region by Missouri Care, Inc. in cooperation with Blue Cross and Blue Shield of Kansas City. Missouri Care, Inc. and Blue Cross and Blue Shield of Kansas City are both independent licensees of the Blue Cross and Blue Shield Association.

microwave ablation in 52 sessions. The median tumor size was 1.8 cm and 1.7 cm in the RFA and microwave ablation groups respectively. Complete ablation or no evidence of residual disease on the first post-ablation contrast enhanced CT (6 weeks), was used as the basis for monitoring for local tumor progression. Complete ablation was reported in 93% (79/85) of the RFA group and 97% (58/60) of the MWA group. The LTPFS rate for RFA versus MWA at 12 month was 69% versus 75%, at 18 months 66% versus 66%, and at 24 months 61% versus 60% respectively. An ablation margin of 5 mm or less was a predictor of shorter LTPFS in both groups while the presence of peri-vascular tumors was a predictor of LTPFS in only the RFA group. The authors noted that while the heat sink effect is a limitation of RFA, MWA might be relatively resistant to the heat sink effect. There were no differences in complication rates between the two modalities.

Uveal melanoma

Uveal melanoma occurs in approximately 5 to 10 million people per million per year, less than 3% of cases presenting with detectable metastatic disease at the time of diagnosis (NCCN, V1.2023). The most common site of metastasis is the liver (90%). NCCN CPG for uveal melanoma (V1.2023) 2A recommendations for liver-directed therapies include embolization and ablative procedures. A number of prospective and retrospective studies have shown a palliative treatment benefit when locoregional therapies are used (Edelhauser, 2012; Gonsalves, 2015; Gonsalves, 2019; Patel, 2005; Ponti, 2020; Tulokas, 2018).

TACE and TAE

Arterial embolization therapy, including TACE and TAE, in the treatment of HCC is based on selective catheter-based infusion of particles targeted to the branch of the hepatic artery feeding the portion of the liver in which the tumor is located. TACE has been investigated to treat resectable, unresectable, and recurrent HCC, as a bridge to liver transplantation, and to treat liver metastases, most commonly from colorectal cancer. TACE of the liver is a proposed alternative to conventional systemic or intra-arterial chemotherapy, and to various nonsurgical ablative techniques, to treat resectable and nonresectable tumors. The rationale for TACE is that infusions of viscous material containing one or more antineoplastic agents may exert synergistic effects: cytotoxicity from the chemotherapy that is potentiated by anoxia in the infarcted region. The liver is especially amenable to such an approach, given its distinct lobular anatomy, the existence of two independent blood supplies, and the ability of healthy hepatic tissue to grow and thus compensate for tissue mass lost during TACE. Another rationale is that TACE delivers effective local doses, while possibly minimizing systemic toxicities associated with oral or intravenous chemotherapy. Prior to the TACE procedure, the patency of the portal vein is demonstrated to ensure an adequate post-treatment hepatic blood supply. A catheter is inserted via the femoral artery and threaded into the hepatic artery and the hepatic vasculature is delineated by angiogram. The initial injection of the viscous embolic chemotherapy mixture is followed by embolization of the arterial blood supply. The TAE procedure is similar, but does not include the injection of a chemotherapy agent.

Federal and State law, as well as contract language including definitions and specific coverage provisions/exclusions, and Medical Policy take precedence over Clinical UM Guidelines and must be considered first in determining eligibility for coverage. The member's contract benefits in effect on the date that services are rendered must be used. Clinical UM Guidelines, which address medical efficacy, should be considered before utilizing medical opinion in adjudication. Medical technology is constantly evolving, and we reserve the right to review and update Clinical UM Guidelines periodically. Clinical UM guidelines are used when the plan performs utilization review for the subject. Due to variances in utilization patterns, each plan may choose whether or not to adopt a particular Clinical UM Guideline. To determine if review is required for this Clinical UM Guideline, please contact the customer service number on the back of the member's card.

No part of this publication may be reproduced, stored in a retrieval system or transmitted, in any form or by any means, electronic, mechanical, photocopying, or otherwise, without permission from the health plan.

© CPT Only – American Medical Association

Healthy Blue is a Medicaid product offered by Missouri Care, Inc., a MO HealthNet Managed Care health plan contracting with the Missouri Department of Social Services. Healthy Blue is administered statewide by Missouri Care, Inc. and administered in the Kansas City service region by Missouri Care, Inc. in cooperation with Blue Cross and Blue Shield of Kansas City. Missouri Care, Inc. and Blue Cross and Blue Shield of Kansas City are both independent licensees of the Blue Cross and Blue Shield Association.

The NCCN CPG for HCC (V1.2023) states the following with Category 2A recommendations in the Principles of Locoregional Therapy - Arterially directed therapies section:

- Locoregional therapy should be considered in patients who are not candidates for surgical curative treatments, or as a part of a strategy to bridge patients for other curative therapies.
- Lesions 3 to 5 cm may be treated to prolong survival using arterially directed therapies, or with combination of an arterially directed therapy and ablation as long as tumor location is accessible for ablation.
- All tumors irrespective of location may be amenable to arterially directed therapies provided that the arterial blood supply to the tumor may be isolated without excessive non-target treatment.
- Unresectable/inoperable lesions > 5cm should be considered for treatment using arterially directed, systemic therapy or EBRT.
- Arterially directed therapies include transarterial bland embolization (TAE) chemoembolization (transarterial chemoembolization [TACE] and TACE with drug-eluting beads [DEB-TACE]) and radioembolization (RE) with yttrium-90 microspheres.
- All arterially directed therapies are relatively contraindicated in patients with bilirubin >3 mg/dL unless segmental injections can be performed. RE with yttrium-90 microspheres has an increased risk of radiation-induced liver disease in patients with bilirubin over 2 mg/dL.
- Arterially directed therapies in highly selected patients have been shown to be safe in the presence of limited tumor invasion of the portal vein.

Early RCTs and meta-analysis have supported the role of embolization procedures as a palliation therapy in unresectable HCC. Ideal candidates for TACE include individuals with preserved liver function and asymptomatic multinodular tumors without vascular invasion or extrahepatic spread not suitable for radical treatments. In this population, TACE can result in increased survival times over no treatment. Individuals who present with more extensive disease may receive little or no benefit from TACE (Bruix, 2005; Bruix 2011; Lau, 2006; Liapi, 2007; Llovet, 2002b; Llovet, 2003; Llovet, 2004; Lo, 2002; Maluccio, 2008; Molinari, 2006).

Kennedy and colleagues (2015) reviewed 18 publications regarding the use of TAE or TACE (n=11) or radioembolization (n=7) in individuals with liver metastasis from a neuroendocrine tumor who are not surgical candidates. The review of these studies by recognized experts in the management of neuroendocrine tumors with liver metastases formed the basis of recommendations from NET-Liver-Metastases Consensus Conference. The workgroup concluded that TAE, TACE and radioembolization therapy can produce objective responses and control symptoms, but none of the techniques showed a clear superiority over the other techniques. TAE compared to TACE have been shown to result in equivalent outcomes, TAE is generally tolerated better due to the absence of chemotherapy (Facciorusso, 2017; Lanza, 2020).

Federal and State law, as well as contract language including definitions and specific coverage provisions/exclusions, and Medical Policy take precedence over Clinical UM Guidelines and must be considered first in determining eligibility for coverage. The member's contract benefits in effect on the date that services are rendered must be used. Clinical UM Guidelines, which address medical efficacy, should be considered before utilizing medical opinion in adjudication. Medical technology is constantly evolving, and we reserve the right to review and update Clinical UM Guidelines periodically. Clinical UM guidelines are used when the plan performs utilization review for the subject. Due to variances in utilization patterns, each plan may choose whether or not to adopt a particular Clinical UM Guideline. To determine if review is required for this Clinical UM Guideline, please contact the customer service number on the back of the member's card.

No part of this publication may be reproduced, stored in a retrieval system or transmitted, in any form or by any means, electronic, mechanical, photocopying, or otherwise, without permission from the health plan.

© CPT Only – American Medical Association

Healthy Blue is a Medicaid product offered by Missouri Care, Inc., a MO HealthNet Managed Care health plan contracting with the Missouri Department of Social Services. Healthy Blue is administered statewide by Missouri Care, Inc. and administered in the Kansas City service region by Missouri Care, Inc. in cooperation with Blue Cross and Blue Shield of Kansas City. Missouri Care, Inc. and Blue Cross and Blue Shield of Kansas City are both independent licensees of the Blue Cross and Blue Shield Association.

TACE has been studied for other indications including large HCC, preoperative shrinkage of resectable HCC, and for tumor types other than HCC and neuroendocrine tumors. Cheng and colleagues (2005a) evaluated the value and limitations of postoperative TACE in preventing recurrence of HCC. In this retrospective study, the authors compared the recurrence rates for a group of 987 individuals with HCC treated with TACE compared to a control group of 643 postoperative individuals with HCC who did not receive TACE. The 6-, 12-, and 18-month recurrence rates for the TACE group compared to the non-TACE group were 22.2% versus 61.6%, 78.0% versus 74.7% and 88.6% versus 80.1%. The difference between the recurrence rate at 6 months was significant ($p < 0.0001$). The authors concluded that TACE had a good effect in preventing recurrence of HCC at 6 months, but the rate of recurrence was less satisfactory in a longer period. The data reported in this trial did not demonstrate that TACE resulted in a significant advantage in quality of life or length of survival for these conditions.

Chua and colleagues (2009) conducted a systematic review of neoadjuvant TACE for resectable HCC, evaluating 18 studies including 3 RCTs and 15 observational studies. The review comprised 3927 individuals, of whom 1293 underwent neoadjuvant TACE. The conclusions were that TACE could be used safely and resulted in high rates of pathologic responses but did not appear to improve disease-free survival in the TACE group. No conclusions could be drawn with respect to OS differences between the TACE and non-TACE groups due to the heterogeneity of the results across studies.

Zhou and colleagues (2013) reported on a meta-analysis of 21 studies evaluating preoperative TACE including 4 RCTs and 17 nonrandomized studies with a total of 3210 participants. Preoperative TACE was given to 1431 individuals with the remaining 1779 serving as controls. The 5-year disease-free survival for preoperative TACE in 18 studies ranged from 7% to 57% and 8% to 49% in the controls. In 16 studies, the 5-year OS for preoperative TACE was 15% to 63% and 19% to 63% in the controls. In the pooled analyses, there were no significant improvements with preoperative TACE versus controls in the 5-year disease-free (32% vs. 30%, $p = 0.17$) and OS (40% vs. 45%, $p = 0.37$). Intra- and extra-hepatic recurrence were also not significantly different in the pooled analyses (51% vs. 54% and 13% vs. 10%; $p = 0.19$, respectively).

Vogl and colleagues (2009) evaluated tumor control and survival in individuals with unresectable liver metastases of colorectal origin that did not respond to systemic chemotherapy and were treated with TACE. Participants were treated at 4-week intervals, with a total of 2,441 TACE procedures performed (mean, 5.3 sessions per participant), using 1 of 3 local chemotherapy protocols. Local tumor control was PR in 68 participants (14.7%), stable disease in 223 participants (48.2%), and progressive disease in 172 participants (37.1%). Median survival from the start of TACE treatments was 14 months. The 1- and 2-year survival rates after TACE were 62% and 28%, respectively. No difference in survival was observed between the 3 different local chemotherapy protocols.

A Cochrane review (Riemsma, 2013) concluded that in individuals with colorectal liver metastases, no significant survival benefit or benefit on extrahepatic recurrence was found when comparing TACE to palliative care. “At present, transarterial (chemo) embolization cannot be recommended outside randomized clinical trials.”

Federal and State law, as well as contract language including definitions and specific coverage provisions/exclusions, and Medical Policy take precedence over Clinical UM Guidelines and must be considered first in determining eligibility for coverage. The member's contract benefits in effect on the date that services are rendered must be used. Clinical UM Guidelines, which address medical efficacy, should be considered before utilizing medical opinion in adjudication. Medical technology is constantly evolving, and we reserve the right to review and update Clinical UM Guidelines periodically. Clinical UM guidelines are used when the plan performs utilization review for the subject. Due to variances in utilization patterns, each plan may choose whether or not to adopt a particular Clinical UM Guideline. To determine if review is required for this Clinical UM Guideline, please contact the customer service number on the back of the member's card.

No part of this publication may be reproduced, stored in a retrieval system or transmitted, in any form or by any means, electronic, mechanical, photocopying, or otherwise, without permission from the health plan.

© CPT Only – American Medical Association

Healthy Blue is a Medicaid product offered by Missouri Care, Inc., a MO HealthNet Managed Care health plan contracting with the Missouri Department of Social Services. Healthy Blue is administered statewide by Missouri Care, Inc. and administered in the Kansas City service region by Missouri Care, Inc. in cooperation with Blue Cross and Blue Shield of Kansas City. Missouri Care, Inc. and Blue Cross and Blue Shield of Kansas City are both independent licensees of the Blue Cross and Blue Shield Association.

Neuroendocrine Tumors

For individuals with hepatic metastasis from neuroendocrine tumors, data in the medical literature confirms that catheter-based arterial embolization procedures, with or without chemotherapy, have a role in the palliative care of individuals with various neuroendocrine tumor symptoms such as carcinoid syndrome (for example, severe flushing, wheezing, and diarrhea), Zollinger-Ellison syndrome, hypoglycemia, severe diabetes, and other neuroendocrine-related manifestations (Christante, 2008, Chen, 2017; Gupta, 2003; Hur, 2013; Maluccio, 2006; Roche, 2003; Ruutiainen, 2007). The treatment has been shown to be useful in diminishing the effect of these symptoms on the individual, consequently producing significant improvements in the quality of life for individuals with neuroendocrine tumors. TACE or TAE is also known to improve pain and control symptoms attributable to the effect of tumor bulk associated with either primary or metastatic liver disease through shrinkage of tumor size.

Egger and colleagues (2020) performed a retrospective review of 248 individuals with unresectable neuroendocrine liver metastases who underwent TACE or TARE. Individuals underwent therapy for the treatment of progressive liver metastases, uncontrolled symptoms, or significant tumor burden. A total of 79% (197) received TARE, the remaining 21% (51) received TACE. There were no differences in the overall complication rate, grade III/IV complication rate or 30-day mortality rate. At the median follow-up period (34 months), there were no significant differences between TARE versus TACE in the median OS (35.9 months versus 50.1 months, $p=0.3$) or PFS (15.9 months versus vs 19.9 months, $p=0.37$). The 5-year OS rates were reported as 42% for TACE and 35% for TARE. Both techniques are safe and effective for the treatment of unresectable neuroendocrine liver metastases.

The NCCN CPG for neuroendocrine tumors of the gastrointestinal tract and/or distant metastases (V2.2022) includes a 2A recommendation to consider hepatic-directed therapy for hepatic-predominant disease including arterial embolization and TACE for individuals with well-differentiated NETs with liver-dominant unresectable metastases (symptomatic, bulky liver disease, or progressive disease). The CPG also notes that drug-eluting embolics are associated with increased hepatobiliary toxicity and are not recommended.

Immunoembolization

Immunoembolization has been proposed as an effective treatment to prolong survival in individuals with uveal melanoma hepatic metastases. Similar to TACE, treatment with immunoembolization involves a cytokine injection, typically granulocyte-macrophage colony-stimulating factor (GM-CSF), into the hepatic arteries followed by embolization of the arteries using embolic agents. The introduction of this biological response modifier is theorized to induce an inflammatory response in the tumor and stimulate a systemic immune response against the tumor. No studies to date have shown that immunoembolization therapy, when compared to TACE or TAE, have improved therapeutic outcomes. The most common adverse event associated with TACE or TAE is post-embolization syndrome which consists of fever, abdominal pain, nausea, vomiting, leukocytosis, and an increase in liver

Federal and State law, as well as contract language including definitions and specific coverage provisions/exclusions, and Medical Policy take precedence over Clinical UM Guidelines and must be considered first in determining eligibility for coverage. The member's contract benefits in effect on the date that services are rendered must be used. Clinical UM Guidelines, which address medical efficacy, should be considered before utilizing medical opinion in adjudication. Medical technology is constantly evolving, and we reserve the right to review and update Clinical UM Guidelines periodically. Clinical UM guidelines are used when the plan performs utilization review for the subject. Due to variances in utilization patterns, each plan may choose whether or not to adopt a particular Clinical UM Guideline. To determine if review is required for this Clinical UM Guideline, please contact the customer service number on the back of the member's card.

No part of this publication may be reproduced, stored in a retrieval system or transmitted, in any form or by any means, electronic, mechanical, photocopying, or otherwise, without permission from the health plan.

© CPT Only – American Medical Association

Healthy Blue is a Medicaid product offered by Missouri Care, Inc., a MO HealthNet Managed Care health plan contracting with the Missouri Department of Social Services. Healthy Blue is administered statewide by Missouri Care, Inc. and administered in the Kansas City service region by Missouri Care, Inc. in cooperation with Blue Cross and Blue Shield of Kansas City. Missouri Care, Inc. and Blue Cross and Blue Shield of Kansas City are both independent licensees of the Blue Cross and Blue Shield Association.

enzymes lasting for a few hours to a few days. This syndrome, which has widely variable manifestations, is usually self-limited and experienced after 80% to 90% of the procedures. The chemotherapeutic and embolizing agents may also cause acute portal vein thrombosis, acute cholecystitis, biliary tract necrosis, pancreatitis, gastric erosions, or ulcers if they are inadvertently injected into these organs. Infection of the necrotic tumor presenting as liver abscess can also occur. Hepatic insufficiency and liver failure, a major treatment-related complication that may result in morbidity, can develop after TACE in individuals with borderline liver function before treatment (Lau, 2008).

In 2008, Sato and colleagues conducted a prospective study to evaluate the safety and feasibility of immunoembolization therapy to treat primary uveal melanoma metastatic unresectable liver tumors. Individuals with stable or responsive disease received immunoembolization with GM-CSF every 4 weeks for a total of 6 treatments (n=371). Participants were grouped into dose-escalated GM-CSF arms: 750 µg, 1000 µg, 1500 µg and 2000 µg. Following the initial 6 treatments, individuals who showed clinical benefit could choose to continue treatment until progression or discontinue treatment but elect re-treatment if they experienced tumor progression. The reported median OS was 14.4 months (95% confidence interval [CI], 11.2 to 22.3 months). The 1-year and 2-year survival rates were 62% (95% CI, 45.0 to 78.1%) and 26% (95% CI, 11.2 to 41.0%), respectively, with a higher dose of GM-CSF associated with longer OS. The authors noted that the OS among a similar set of individuals who received chemoembolization ranged from 5 to 15 months. This study did not identify any safety concerns surrounding immunoembolization therapy. However, the study was not designed to evaluate the effectiveness of immunoembolization therapy and results do not support that immunotherapy is as effective as other hepatic arterial directed therapies such as TAE or TACE.

Valsecchi and associates evaluated the effect of immunoembolization in individuals with uveal melanoma with liver-only metastasis in a double-blind phase II randomized study (2015). Individuals with metastatic uveal melanoma to the liver with no extrahepatic metastasis and at least one measurable hepatic lesion were randomly assigned to undergo immunoembolization or TAE. Treatment involved an injection of GM-CSF (n=25) or normal saline (n=27) into the hepatic artery followed by injection of an embolization agent. Treatment was repeated every 4 weeks until disease progression, extrahepatic metastases development, or there was unacceptable toxicity. The overall response rate (ORR) including complete responses and partial responses was chosen as the primary endpoint. A 30% ORR was used as a surrogate of a clinically meaningful effect. In the immunoembolization arm, 5 individuals showed a partial response, 12 individuals showed stable disease and 8 individuals showed tumor progression. In the TAE arm, 3 individuals showed a partial response, 19 individuals had stable disease and 5 individuals showed disease progression. There were no complete responses in either group. The estimated ORR in the immunoembolization group was 21.2% and the median OS was 21.5 months. In the TAE group, the ORR was 16.7% and the OS was 17.2 months. The authors concluded that immunoembolization appears to be safe and potentially effective to treat uveal melanoma with liver-only metastasis, which has an extremely poor prognosis and a short OS. This study is associated with a number of limitations. While uveal melanoma is the most common primary intraocular malignant tumor in adults in the U.S. and liver metastatic disease is common, the study

Federal and State law, as well as contract language including definitions and specific coverage provisions/exclusions, and Medical Policy take precedence over Clinical UM Guidelines and must be considered first in determining eligibility for coverage. The member's contract benefits in effect on the date that services are rendered must be used. Clinical UM Guidelines, which address medical efficacy, should be considered before utilizing medical opinion in adjudication. Medical technology is constantly evolving, and we reserve the right to review and update Clinical UM Guidelines periodically. Clinical UM guidelines are used when the plan performs utilization review for the subject. Due to variances in utilization patterns, each plan may choose whether or not to adopt a particular Clinical UM Guideline. To determine if review is required for this Clinical UM Guideline, please contact the customer service number on the back of the member's card.

No part of this publication may be reproduced, stored in a retrieval system or transmitted, in any form or by any means, electronic, mechanical, photocopying, or otherwise, without permission from the health plan.

© CPT Only – American Medical Association

Healthy Blue is a Medicaid product offered by Missouri Care, Inc., a MO HealthNet Managed Care health plan contracting with the Missouri Department of Social Services. Healthy Blue is administered statewide by Missouri Care, Inc. and administered in the Kansas City service region by Missouri Care, Inc. in cooperation with Blue Cross and Blue Shield of Kansas City. Missouri Care, Inc. and Blue Cross and Blue Shield of Kansas City are both independent licensees of the Blue Cross and Blue Shield Association.

included only 52 participants. The study included an evaluation of the timing and magnitude of the inflammatory reaction after immunoembolization as well as ORR, OS and PFS. The TAE arm was designed to serve as a control only for the immunologic outcomes. The study design was not created with the intent to compare survival and progression free survival between the arms and was underpowered.

TACE with Drug-Loaded Microspheres or Drug-Eluting Beads (DEBs)

The development of DEBs or injectable microspheres loaded with chemotherapy is being considered as a drug delivery system for intraarterial treatment of hepatic lesions during TACE. The U.S. Food and Drug Administration (FDA) has not cleared TACE-administered DEBs or microspheres loaded with chemotherapeutic agents for sale or distribution in the United States. However, the FDA has stand-alone approvals for chemotherapeutic and embolic agents used with TACE that are not specifically approved as combination therapy when administered during TACE. Specific chemotherapeutic agents may be approved for a number of oncologic indications and several embolic beads are FDA-approved for “embolization of hypervascular tumors and arteriovenous malformations” (FDA, 2014). Several brands of DEBs include, but are not limited to, DC Bead™, DEBDOX™ -loaded with doxorubicin, and DEBIRI™ - loaded with irinotecan (Boston Scientific, Marlborough, MA) and HepaSphere™ Microspheres (Merit Medical, Inc., South Jordan, UT)- loaded with doxorubicin. A number of studies evaluating the use of DEBs to treat colorectal cancer on unresectable HCC have been completed. These studies are limited by several factors, including small size, lack of standardized treatment within the groups, lack of a control group and high drop-out rates (Grosso, 2008; Lee, 2017; Martin, 2009; Martin, 2015; Poggi, 2008; Poon, 2007; Reyes, 2009; Varela, 2007).

Richardson and colleagues (2013) systematically reviewed an RCT and five observational studies (n=235) on the use of TACE with irinotecan-DEBs for the treatment of unresectable colorectal liver metastasis. Survival times ranged from a median of 15.2 months to 25 months. The most common adverse event was postembolization syndrome (abdominal pain, nausea, and vomiting) followed by hypertension. In the RCT in this review (Fiorentini, 2012), 74 participants were randomly allocated to TACE with irinotecan-DEBs (n=36) or systemic irinotecan, fluorouracil and leucovorin (FOLFIRI) (n=38). The OS in the irinotecan-DEBs group was significantly longer with a median OS of 22 months (95% CI, 21-23 months) compared to 15 months (95% CI, 12-18 months) for the FOLFIRI chemotherapy group (p=0.031). Progression-free survival was 7 months in the irinotecan-DEBs group compared to 4 months in the FOLFIRI group; and the difference between groups was statistically significant (p=0.006, long-rank). Extrahepatic progression occurred in all participants by the end of the study, at a median time of 13 months in the irinotecan-DEBs group compared to 9 months in the FOLFIRI group; however, a statistically significant difference between groups was not observed (p=0.064, log-rank).

A number of studies have compared of TACE therapy with DEBs to TACE or TAE in the treatment of unresectable HCC. Although these studies suggest that there might be a survival benefit associated with the use of DEBs, they fail to report conclusive evidence to support that DEB TACE resulted in statistically significant improved objective

Federal and State law, as well as contract language including definitions and specific coverage provisions/exclusions, and Medical Policy take precedence over Clinical UM Guidelines and must be considered first in determining eligibility for coverage. The member's contract benefits in effect on the date that services are rendered must be used. Clinical UM Guidelines, which address medical efficacy, should be considered before utilizing medical opinion in adjudication. Medical technology is constantly evolving, and we reserve the right to review and update Clinical UM Guidelines periodically. Clinical UM guidelines are used when the plan performs utilization review for the subject. Due to variances in utilization patterns, each plan may choose whether or not to adopt a particular Clinical UM Guideline. To determine if review is required for this Clinical UM Guideline, please contact the customer service number on the back of the member's card.

No part of this publication may be reproduced, stored in a retrieval system or transmitted, in any form or by any means, electronic, mechanical, photocopying, or otherwise, without permission from the health plan.

© CPT Only – American Medical Association

Healthy Blue is a Medicaid product offered by Missouri Care, Inc., a MO HealthNet Managed Care health plan contracting with the Missouri Department of Social Services. Healthy Blue is administered statewide by Missouri Care, Inc. and administered in the Kansas City service region by Missouri Care, Inc. in cooperation with Blue Cross and Blue Shield of Kansas City. Missouri Care, Inc. and Blue Cross and Blue Shield of Kansas City are both independent licensees of the Blue Cross and Blue Shield Association.

response rates or survival benefits when compared to TACE or TAE alone (Dhanasekaran, 2010; Lammer, 2010 RCT; Malagari, 2010). In addition, a number of meta-analysis and systematic reviews compare the safety and efficacy of conventional TACE to DEB-TACE in the treatment of unresectable HCC and have concluded that the evidence is inconclusive regarding the clinical effectiveness of DEB therapy as conventional TACE or TAE therapy (Do Minh, 2017; Facciorusso, 2016a; Hui, 2015; Katsanos, 2017; Wang, 2020; Xie, 2015).

The NCCN CPG for hepatobiliary cancer (V2.2023) described several studies comparing DEB-TACE to conventional TACE in the treatment of unresectable HCC. The studies did not show a clear superiority of DEB-TACE when compared to TACE in the treatment of this population; however, there were some reported decreased in side effects and tolerability. The NCCN summarized the evidence noting “However, these results are from underpowered studies and need to be confirmed in large prospective studies.”

SIRT/TARE

SIRT, also known as TARE, relies on targeted delivery of small beads (microspheres) impregnated with radioactive ⁹⁰Y to cure or palliate unresectable hepatic tumors by improving loco-regional control. The rationale for SIRT is based on the following: (1) the liver parenchyma is sensitive to radiation; (2) the hepatic circulation is uniquely organized, whereby tumors greater than 0.5 cm rely on the hepatic artery for blood supply while normal liver is primarily perfused via the portal vein; and (3) ⁹⁰Y is a pure beta emitter with a relatively limited effective range and short half-life that helps focus the radiation and minimize its spread. Candidates for SIRT are examined by liver angiography and technetium (^{99m}Tc) lung scan to rule out aberrant hepatic vasculature or significant lung shunting that would permit diffusion of injected microspheres.

Currently, two commercial forms of ⁹⁰Y microspheres are available: TheraSpheres™ (Boston Scientific, Marlborough, MA) are glass beads bound to ⁹⁰Y, and SIR-Sphere® (Sirtex Medical Inc., Lake Forest, IL), in which ⁹⁰Y is bound to resin beads. Non-commercial forms are used mostly outside the U.S. While the commercial products use the same radioisotope (⁹⁰Y) and have the same target dose (100 Gy), they differ in microsphere size profile, base material (i.e., glass versus resin, respectively) and size of commercially available doses. These physical characteristics of the active and inactive ingredients affect the flow of microspheres during injection, their retention at the tumor site, spread outside the therapeutic target region, and dosimetry calculations. Note also that the U.S. FDA granted PMA of SIR-Sphere, for use in combination with 5-fluorouridine (5-FU) chemotherapy by adjuvant hepatic artery chemotherapy (IHAC), to treat unresectable hepatic metastases from CRC cancer. In contrast, TheraSpheres is approved and indicated for use as monotherapy to treat or as a neoadjuvant therapy to transplantation or surgery in individuals with unresectable hepatocellular cancer (HCC). In addition, therapy is also indicated when there is partial or branch portal vein thrombosis/occlusion in those with HCC. For these reasons, results obtained with one product do not necessarily apply to other commercial (or non-commercial) products. The uses of both technologies are additionally regulated by the U.S. Nuclear Regulatory Commission (NRC).

Federal and State law, as well as contract language including definitions and specific coverage provisions/exclusions, and Medical Policy take precedence over Clinical UM Guidelines and must be considered first in determining eligibility for coverage. The member's contract benefits in effect on the date that services are rendered must be used. Clinical UM Guidelines, which address medical efficacy, should be considered before utilizing medical opinion in adjudication. Medical technology is constantly evolving, and we reserve the right to review and update Clinical UM Guidelines periodically. Clinical UM guidelines are used when the plan performs utilization review for the subject. Due to variances in utilization patterns, each plan may choose whether or not to adopt a particular Clinical UM Guideline. To determine if review is required for this Clinical UM Guideline, please contact the customer service number on the back of the member's card.

No part of this publication may be reproduced, stored in a retrieval system or transmitted, in any form or by any means, electronic, mechanical, photocopying, or otherwise, without permission from the health plan.

© CPT Only – American Medical Association

Healthy Blue is a Medicaid product offered by Missouri Care, Inc., a MO HealthNet Managed Care health plan contracting with the Missouri Department of Social Services. Healthy Blue is administered statewide by Missouri Care, Inc. and administered in the Kansas City service region by Missouri Care, Inc. in cooperation with Blue Cross and Blue Shield of Kansas City. Missouri Care, Inc. and Blue Cross and Blue Shield of Kansas City are both independent licensees of the Blue Cross and Blue Shield Association.

The NCCN CPGs for colon and rectal cancer (V1.2023) include the following recommendations:

- When hepatic metastatic disease is not optimally resectable based on insufficient remnant liver volume, approaches using preoperative portal vein embolization, staged liver resection, or yttrium-90 radioembolization can be considered.
- Arterially directed catheter therapy, and in particular yttrium-90 microsphere selective internal radiation, is an option in highly selected patients with chemotherapy-resistant/-refractory disease and with predominant hepatic metastases.

The American College of Radiology (ACR) Appropriateness Criteria for the management of liver cancer (revised 2022) note that TARE does not appear to provide a survival benefit when used concurrently with systemic chemotherapy as a first line treatment, but is associated with a survival benefit when in individuals with CRC liver metastases “that have failed multiple prior systemic chemotherapy options”.

Wasan and colleagues (2017) evaluated the use of SIRT with chemotherapy compared to chemotherapy alone as a first-line treatment of liver metastases from CRC. The authors performed a combined analysis of 3 multicenter, randomized, phase 3 trials evaluating overall survival. The addition of SIRT in early treatment did not show a benefit in overall survival. The authors note that the data suggest that SIRT does provide clinical benefits in individuals with CRC liver-dominant disease following chemotherapy failure, but currently the evidence does not support the use of SIRT at an earlier point.

Mulcahy and colleagues (2021) reported on the results of a randomized, open-label, international, multicenter, phase III trial which evaluated the impact of TARE as an adjunctive therapy with second-line systemic chemotherapy in the treatment of colorectal liver metastases (EPOCH). Individuals with metastatic colorectal carcinoma of the liver who had progressed on first-line chemotherapy were included. Participants were randomized to receive second-line chemotherapy with (n=215) or without (n=213) TARE. The groups who received the study therapy, 187 individuals in the TARE group and 191 in the control group were balanced. The addition of TARE to second-line chemotherapy did increase median PFS from 7.2 months to 8 months and the hepatic PFS increased from 7.2 months to 9.1 months compared to the control group, but no improved OS.

In a prospective, randomized phase 2 trial, Salem and colleagues (2017) compared TACE (n=21) and yttrium-90 microspheres (Y90) (n=24) therapy for the treatment of individuals with unresectable, unablated HCC. The primary endpoint was chosen as time to progression (TTP). The median TTP was significantly longer in the Y90 group versus the TACE group (not reached at more than 26 months versus 6.8 months, p=0.0012; HR: 0.122, 95% CI, 0.027–0.557, p=0.007). There were 4 cases delayed grade 3+ toxicities in the TACE group compared to 3 cases in the Y90 group. There was no significant difference in the OS between the groups. An earlier retrospective review (Salem, 2011) comparing TACE (n=122) and TARE (n=123) (Salem, 2011) found similar results. When compared to TACE, TARE therapy resulted in longer TTP, but there were no significant differences in OS.

Federal and State law, as well as contract language including definitions and specific coverage provisions/exclusions, and Medical Policy take precedence over Clinical UM Guidelines and must be considered first in determining eligibility for coverage. The member's contract benefits in effect on the date that services are rendered must be used. Clinical UM Guidelines, which address medical efficacy, should be considered before utilizing medical opinion in adjudication. Medical technology is constantly evolving, and we reserve the right to review and update Clinical UM Guidelines periodically. Clinical UM guidelines are used when the plan performs utilization review for the subject. Due to variances in utilization patterns, each plan may choose whether or not to adopt a particular Clinical UM Guideline. To determine if review is required for this Clinical UM Guideline, please contact the customer service number on the back of the member's card.

No part of this publication may be reproduced, stored in a retrieval system or transmitted, in any form or by any means, electronic, mechanical, photocopying, or otherwise, without permission from the health plan.

© CPT Only – American Medical Association

Healthy Blue is a Medicaid product offered by Missouri Care, Inc., a MO HealthNet Managed Care health plan contracting with the Missouri Department of Social Services. Healthy Blue is administered statewide by Missouri Care, Inc. and administered in the Kansas City service region by Missouri Care, Inc. in cooperation with Blue Cross and Blue Shield of Kansas City. Missouri Care, Inc. and Blue Cross and Blue Shield of Kansas City are both independent licensees of the Blue Cross and Blue Shield Association.

Vente and colleagues (2009) conducted a meta-analysis of the literature addressing SIRT for unresectable liver metastases. The authors included all forms of SIRT, including SIR-Spheres and TheraSpheres, analyzing 30 articles that included 1217 subjects. For individuals with CRC metastases, a total of 19 eligible studies, which included 792 subjects, were included in the analysis. Of these, 195 had received SIRT as a first-line treatment and 486 received SIRT as salvage therapy. There was a significant difference in response when used for first-line therapy versus salvage, with the response rates reported as 91% and 79% respectively ($p=0.07$). The median survival time varied between 6.7 to 17 months, irrespective of microsphere type, chemotherapy regimen, disease stage, or salvage versus first-line therapy. Median survival from time of diagnosis ranged from 10.8 to 29.4 months. For individuals with HCC, the authors included 14 studies in their analysis. These studies included 425 subjects who underwent SIRT therapy. Of these studies, only 12 reported on tumor response, leaving 318 subjects. The authors noted that treatment with resin microspheres (e.g., SIR-Spheres) was associated with a significantly higher response rate when compared to glass microspheres (e.g., TheraSpheres) (89% versus 78%, $p=0.02$). Median survival was reported in only seven studies. Median survival from time of SIRT treatment varied between 7.1 to 21 months. Median survival from time of diagnosis or recurrence was reported to be between 9.4 to 24 months.

Six meta-analyses have been published comparing the safety and efficacy of TACE compared to SIRT in the treatment of unresectable HCC (Facciorusso, 2016; Katsanos, 2017; Lobo, 2016; Ludwig, 2017; Yang, 2018; and Zhang, 2015). The published literature chosen for inclusion in the analyses varied on SIRT's utility as primary versus salvage treatment and on outcomes of interest, some of which included tumor response, survival and quality of life measures. Other variations between studies included subjects with PVT or minimal extra-hepatic disease while others excluded for any evidence of PVT or extra-hepatic disease. Three of the six meta-analyses concluded that outcomes, including survival, appear comparable or better when comparing SIRT to TACE for unresectable HCC, and SIRT resulted in fewer complications and less hospitalization when compared to TACE. Zhang (2015) reported that only three of the eight studies chosen for inclusion in their analysis reported on OS but among them, SIRT was found to have a statistically significant survival advantage over TACE (HR=0.74, 95% CI, 0.61-0.90; $p=0.002$). Although OS appeared to be improved in those who received SIRT versus TACE, Zhang (2015) also reported that no beneficial effect was seen in SIRT recipients in the outcomes of complications (other than abdominal pain), tumor response or over-all tumor control. Yang (2018) conducted their analysis by reviewing data from nine observational studies and 1 moderate bias-risk RCT. Although 1-year survival rates were comparable, 2-year OS favored SIRT with marginal significance ($p=0.3$). Ludwig (2017) similarly found a survival benefit with SIRT but no significant difference in tumor response. Katsanos (2017) conducted a very large analysis with 55 RCTs ($n=5763$) and conversely concluded that "Chemoembolization [e.g., TACE] combined with external radiotherapy or local liver ablation may significantly improve tumor response and patient survival rates over embolization monotherapies [for example SIRT]," but included the caveat that evidence is of low to moderate quality due to clinical diversity of studies. The contradictory findings amongst and within the meta-analyses does not provide a high-level of evidence in support of the safety and efficacy of SIRT relative to TACE in individuals with unresectable HCC.

Federal and State law, as well as contract language including definitions and specific coverage provisions/exclusions, and Medical Policy take precedence over Clinical UM Guidelines and must be considered first in determining eligibility for coverage. The member's contract benefits in effect on the date that services are rendered must be used. Clinical UM Guidelines, which address medical efficacy, should be considered before utilizing medical opinion in adjudication. Medical technology is constantly evolving, and we reserve the right to review and update Clinical UM Guidelines periodically. Clinical UM guidelines are used when the plan performs utilization review for the subject. Due to variances in utilization patterns, each plan may choose whether or not to adopt a particular Clinical UM Guideline. To determine if review is required for this Clinical UM Guideline, please contact the customer service number on the back of the member's card.

No part of this publication may be reproduced, stored in a retrieval system or transmitted, in any form or by any means, electronic, mechanical, photocopying, or otherwise, without permission from the health plan.

© CPT Only – American Medical Association

Healthy Blue is a Medicaid product offered by Missouri Care, Inc., a MO HealthNet Managed Care health plan contracting with the Missouri Department of Social Services. Healthy Blue is administered statewide by Missouri Care, Inc. and administered in the Kansas City service region by Missouri Care, Inc. in cooperation with Blue Cross and Blue Shield of Kansas City. Missouri Care, Inc. and Blue Cross and Blue Shield of Kansas City are both independent licensees of the Blue Cross and Blue Shield Association.

Ragoni (2016) conducted a systematic review and meta-analyses to evaluate the efficacy and safety of SIRT in intermediate-advanced HCC, with 21 studies included in the analysis. Only three comparative studies were identified (SIRT versus TACE or sorafenib), two of which were RCTs, the rest were observational cohorts; all were deemed to be of low to medium methodological quality. Authors concluded that evidence supporting the use of SIRT in HCC is largely based on retrospective and cohort studies and that SIRT appears to be a valid treatment option for intermediate-advanced stage HCC.

In 2017, a manufacturer-sponsored, open-label, phase 3, randomized controlled clinical trial was conducted comparing the safety and efficacy of SIRT with sorafenib (Nexavar[®]; Bayer HealthCare Pharmaceuticals Inc., Whippany, NJ) in locally advanced and inoperable HCC (Vilgrain, 2017). Eligible participants were at least 18 years of age, had an ECOG status of 0-1, previous treatment with TACE, and a Child-Pugh liver function class of A or B. A total of 406 participants were randomized to one of the two treatment groups either SIRT (n=184) or sorafenib (n=222). After a median follow-up of approximately 28 months, OS was 8.0 months in the SIRT group and 9.9 months in the sorafenib group (HR=1.15, 95% CI, 0.94-1.41; p=0.18). Reporting of adverse events did not significantly differ between study arms and 19 treatment-related deaths occurred in the SIRT group compared to only 12 in the sorafenib group. In this industry-sponsored, phase 3 trial, SIRT did not demonstrate superior safety or efficacy over sorafenib in the treatment of unresectable HCC.

The FDA labeling for TheraSpheres (2014) and Sir-Spheres (2019) state that the following tests are recommended before treatment:

- A hepatic angiogram should be performed to establish arterial anatomy of the liver;
- A nuclear medicine break-through scan (intrahepatic technetium MAA Scan or Tc-99 MAA) to evaluate hepatic flow to gastrointestinal tract and/or pulmonary shunting. If a port has been inserted, this test can be performed through the port;
- Serologic tests of liver function should be performed to determine the extent of liver function/damage.

Appropriate imaging studies are recommended to determine the extent of disease. These may include chest x-ray, CT scan of chest and abdomen, abdominal ultrasound and a bone scan.

Histotripsy

Histotripsy, a nonthermal focal ablative therapy, has been proposed as an alternative treatment of liver lesions. Histotripsy utilizes short, high-pressure bursts of high-intensity focused ultrasound to induce tissue destruction via acoustic cavitation. The benefits of non-thermal focal ablative therapy include avoidance of any heat sink effects which is theorized to allow histotripsy to be used in highly vascular areas (Hendricks-Wenger, 2021). A phase I trial provided the initial safety and efficacy data regarding the use of hepatic histotripsy in individuals with

Federal and State law, as well as contract language including definitions and specific coverage provisions/exclusions, and Medical Policy take precedence over Clinical UM Guidelines and must be considered first in determining eligibility for coverage. The member's contract benefits in effect on the date that services are rendered must be used. Clinical UM Guidelines, which address medical efficacy, should be considered before utilizing medical opinion in adjudication. Medical technology is constantly evolving, and we reserve the right to review and update Clinical UM Guidelines periodically. Clinical UM guidelines are used when the plan performs utilization review for the subject. Due to variances in utilization patterns, each plan may choose whether or not to adopt a particular Clinical UM Guideline. To determine if review is required for this Clinical UM Guideline, please contact the customer service number on the back of the member's card.

No part of this publication may be reproduced, stored in a retrieval system or transmitted, in any form or by any means, electronic, mechanical, photocopying, or otherwise, without permission from the health plan.

© CPT Only – American Medical Association

Healthy Blue is a Medicaid product offered by Missouri Care, Inc., a MO HealthNet Managed Care health plan contracting with the Missouri Department of Social Services. Healthy Blue is administered statewide by Missouri Care, Inc. and administered in the Kansas City service region by Missouri Care, Inc. in cooperation with Blue Cross and Blue Shield of Kansas City. Missouri Care, Inc. and Blue Cross and Blue Shield of Kansas City are both independent licensees of the Blue Cross and Blue Shield Association.

Locoregional Techniques for Treating Primary and Metastatic Liver Malignancies

hepatocellular carcinoma and hepatic metastasis (Vidal-Jove, 2022). A total of 8 individuals with multifocal liver tumors were followed for 8 weeks post-procedure. There were no significant procedure related events. The study focused on technical safety and did not address cancer follow-up.

The HistoSonicx[®] System (HistoSonics, Ann Arbor, MI) is an automated, external sonic beam therapy platform which will be intended for ablative tissue in the liver. Two single-arm, non-randomized prospective trials are underway to evaluate the safety and efficacy of this system in the treatment of primary or metastatic liver tumors. Participants will be followed for 5 years post-procedure (NCT04572633, NCT04573881).

There are no published studies evaluating the treatment effects of histotripsy. The current evidence regarding the histotripsy procedure does not support that this form of locally ablative therapy is a clinically appropriate treatment of hepatic malignancies.

Bridge to Liver Transplantation

As the incidence of HCC continues to rise and availability of donor organs remains low, the waiting time for potentially curative therapy with orthotopic liver transplantation (OLT) increases. Heckman (2008) noted the incidence of disease progression while listed for transplant was 10-23%. Various technologies have been explored to maintain transplant eligibility by controlling disease progression, of which transcatheter arterial chemoembolization (TACE) and RFA were the most frequently studied. A “bridge” to liver transplant involves ablative techniques to minimize and control disease progression to allow individuals with limited HCC to remain eligible on the OLT waitlist. The goal of bridging is to prevent drop-off from the waiting list and to improve post-transplant survival (DuBay, 2011; Lee, 2020).

Bridge therapy is typically recommended when predicted liver transplant times are likely to exceed 6 months. The majority of studies include a combination of therapies rather than a sole therapy. A number of locoregional therapies have been recognized as successful bridging techniques to maintain transplant eligibility and there is no evidence to support the superiority of any one technique in those studied. In those individuals who are able to achieve a complete response from locoregional therapy prior to transplant, bridging therapy may improve post-transplant survival (Agopian, 2017; Braat, 2016; Bauschke, 2020; Cheng, 2005b; Kulik, 2018; Lee, 2017; Lewandowski, 2009; Obed, 2007).

The current Organ Procurement and Transplantation Network (OPTN) and United Network for Organ Sharing (UNOS) allocation policy (2019) provides incentives to use loco-regional therapies to downsize tumors to T2 status and to prevent progression while on the transplant wait list. In addition, the OPTN/UNOS policy implicitly recognizes the role of loco-regional therapy in the pre-transplant setting. These indications are in part related to the current OPTN/UNOS liver allocation scoring system referred to as the Model for End-Stage Liver Disease (MELD), for adults ages 12 and older, and the Pediatric End-stage Liver Disease (PELD) scoring system for

Federal and State law, as well as contract language including definitions and specific coverage provisions/exclusions, and Medical Policy take precedence over Clinical UM Guidelines and must be considered first in determining eligibility for coverage. The member's contract benefits in effect on the date that services are rendered must be used. Clinical UM Guidelines, which address medical efficacy, should be considered before utilizing medical opinion in adjudication. Medical technology is constantly evolving, and we reserve the right to review and update Clinical UM Guidelines periodically. Clinical UM guidelines are used when the plan performs utilization review for the subject. Due to variances in utilization patterns, each plan may choose whether or not to adopt a particular Clinical UM Guideline. To determine if review is required for this Clinical UM Guideline, please contact the customer service number on the back of the member's card.

No part of this publication may be reproduced, stored in a retrieval system or transmitted, in any form or by any means, electronic, mechanical, photocopying, or otherwise, without permission from the health plan.

© CPT Only – American Medical Association

Healthy Blue is a Medicaid product offered by Missouri Care, Inc., a MO HealthNet Managed Care health plan contracting with the Missouri Department of Social Services. Healthy Blue is administered statewide by Missouri Care, Inc. and administered in the Kansas City service region by Missouri Care, Inc. in cooperation with Blue Cross and Blue Shield of Kansas City. Missouri Care, Inc. and Blue Cross and Blue Shield of Kansas City are both independent licensees of the Blue Cross and Blue Shield Association.

candidates younger than 12 years of age. The MELD score is a continuous disease severity scale incorporating serum bilirubin, prothrombin time (for example, international normalized ratio-INR), and serum creatinine into an equation, producing a number ranging from 6 (less ill) to 40 (gravely ill). The MELD score estimates how urgently the individual needs a liver transplant within the next 3 months. PELD is similar to MELD but uses additional factors to recognize the specific growth and development needs of children. PELD scores may also range higher or lower than the range of MELD scores. The PELD scoring system includes measures of serum bilirubin, INR, albumin, growth failure, and whether the child is less than 1 year old. Candidates that meet the staging and imaging criteria specified in the OPTN/UNOS Allocation of Livers and Liver-Intestines Policy, Candidates with Hepatocellular Carcinoma (HCC) sections 9.3.G.iv-v may receive extra priority on the "Waiting List." A candidate with an HCC tumor that is stage T2 may be registered at a MELD/PELD score equivalent to a 15% risk of candidate death within 3 months if additional criteria are also met. OPTN/UNOS defines Stage T2 lesions as:

- One lesion greater than or equal to 2 cm and less than or equal to 5 cm; or,
- Two or three lesions each greater than or equal to 1 cm and less than or equal to 3 cm in size.

The largest dimension of each tumor is used to report the size of HCC lesions. Nodules less than 1 cm are indeterminate and cannot be considered for additional priority. Past loco-regional treatment for HCC (OPTN Class 5 [T2] lesion or biopsy proven prior to ablation) are eligible for automatic priority.

The NCCN CPG for hepatocellular carcinoma (V1,2023) states:

Bridge therapy is used to decrease tumor progression and the dropout rate from the liver transplantation waiting list. A number of studies have investigated the role of locoregional therapies as a bridge to liver transplantation in patients on a waiting list. These studies included RFA/microwave ablation (MWA), transarterial embolization (TAE), TACE, including conventional TACE and TACE with drug-eluting beads (DEB-TACE), selective internal radiotherapy (SIRT) or radioembolization (TARE) with Y-90 microspheres, EBRT, and TACE followed by EBRT as "bridge" therapies.

Limitations of these studies include size and heterogeneity of the study populations; however, the NCCN CPG states, "Nevertheless, the use of bridge therapy in this setting is increasing, and it is administered at most NCCN Member Institutions, especially in areas where there are long wait times for a transplant."

The AASLD (Gervais, 2011) lists the following recommendations:

Local ablation is safe and effective therapy for patients who cannot undergo resection, or as a bridge to transplantation. Alcohol injection and radiofrequency are equally effective for tumors <2 cm.

However, the necrotic effect of radiofrequency ablation is more predictable in all tumor sizes and in addition its efficacy is clearly superior to that of alcohol injection in larger tumors.

Federal and State law, as well as contract language including definitions and specific coverage provisions/exclusions, and Medical Policy take precedence over Clinical UM Guidelines and must be considered first in determining eligibility for coverage. The member's contract benefits in effect on the date that services are rendered must be used. Clinical UM Guidelines, which address medical efficacy, should be considered before utilizing medical opinion in adjudication. Medical technology is constantly evolving, and we reserve the right to review and update Clinical UM Guidelines periodically. Clinical UM guidelines are used when the plan performs utilization review for the subject. Due to variances in utilization patterns, each plan may choose whether or not to adopt a particular Clinical UM Guideline. To determine if review is required for this Clinical UM Guideline, please contact the customer service number on the back of the member's card.

No part of this publication may be reproduced, stored in a retrieval system or transmitted, in any form or by any means, electronic, mechanical, photocopying, or otherwise, without permission from the health plan.

© CPT Only – American Medical Association

Healthy Blue is a Medicaid product offered by Missouri Care, Inc., a MO HealthNet Managed Care health plan contracting with the Missouri Department of Social Services. Healthy Blue is administered statewide by Missouri Care, Inc. and administered in the Kansas City service region by Missouri Care, Inc. in cooperation with Blue Cross and Blue Shield of Kansas City. Missouri Care, Inc. and Blue Cross and Blue Shield of Kansas City are both independent licensees of the Blue Cross and Blue Shield Association.

The Society of Interventional Radiology's *Quality Improvement Guidelines for Transarterial Chemoembolization and Embolization of Hepatic Malignancy* (Gaba, 2017) states that TACE may be indicated as a bridge to liver transplantation for individuals with liver-dominant hepatic malignancies.

Hepatocellular Carcinoma in Individuals Who May Become Eligible for Liver Transplantation

Downstaging therapy is defined as treatment used to reduce the tumor burden in individuals without distant metastasis but do have more advanced HCC whose tumor characteristics are beyond the accepted transplant criteria (NCCN, V1.2023). TACE is the most common technique used, however, the choice of technique used is influenced by multiple factors, such as tumor size/number, location, liver function, and individual center experience (Kulik, 2018). A number of studies support the use of locoregional therapies as a downstaging technique, with TACE being the most widely studied method (Chapman, 2008; Heckman, 2008).

In 2020 retrospective study, Lee and colleagues evaluated the long-term outcomes of individuals who underwent liver transplantation with or without downstaging or bridging therapy. Individuals with HCC without extrahepatic metastasis who underwent TACE (n=409), RFA (n=50), resection (n=13) radiation (n=5) or combination therapy (n=211) treatment were included in the review. An individual was considered to achieve a successful downstaging (SD) when there was a reduction in the number and size of viable tumors to within the Milan criteria. SD outcomes were associated with improved recurrence-free survival (RFS) and OS when compared to those who experience downstaging failure or disease progression. Individuals with SD prior to liver transplantation achieved better RFS when compared to individuals who did not undergo downstaging prior to liver transplantation.

Yao and associates (2015) compared the long-term outcomes of individuals with HCC who underwent downstaging to prior to liver transplantation (n=118) to individuals who did not require downstaging prior to liver transplantation (n=488). Tumor downstaging was not successful in 41 individuals (34.7%) Individuals who underwent successful downstaging achieved similar Kaplan-Meier 1- and 5-year post-transplant survival compared to those who did not undergo downstaging (93.4% and 77.8% versus 94.3% and 81%, respectively; p=0.69). While the study did include individuals with 4-5 lesions (n=14), the size of this group precludes drawing firm conclusions about the efficacy of downstaging in this subgroup. The authors reported successful post-transplant outcomes following downstaging but noted "We believe that there are upper limits in tumor size and number beyond which down-staging is not likely to be successful and the outcome may be significantly worse."

The NCCN CPG for hepatocellular cancers (V1.2023), principles of surgery, includes the following recommendation:

Federal and State law, as well as contract language including definitions and specific coverage provisions/exclusions, and Medical Policy take precedence over Clinical UM Guidelines and must be considered first in determining eligibility for coverage. The member's contract benefits in effect on the date that services are rendered must be used. Clinical UM Guidelines, which address medical efficacy, should be considered before utilizing medical opinion in adjudication. Medical technology is constantly evolving, and we reserve the right to review and update Clinical UM Guidelines periodically. Clinical UM guidelines are used when the plan performs utilization review for the subject. Due to variances in utilization patterns, each plan may choose whether or not to adopt a particular Clinical UM Guideline. To determine if review is required for this Clinical UM Guideline, please contact the customer service number on the back of the member's card.

No part of this publication may be reproduced, stored in a retrieval system or transmitted, in any form or by any means, electronic, mechanical, photocopying, or otherwise, without permission from the health plan.

© CPT Only – American Medical Association

Healthy Blue is a Medicaid product offered by Missouri Care, Inc., a MO HealthNet Managed Care health plan contracting with the Missouri Department of Social Services. Healthy Blue is administered statewide by Missouri Care, Inc. and administered in the Kansas City service region by Missouri Care, Inc. in cooperation with Blue Cross and Blue Shield of Kansas City. Missouri Care, Inc. and Blue Cross and Blue Shield of Kansas City are both independent licensees of the Blue Cross and Blue Shield Association.

Locoregional Techniques for Treating Primary and Metastatic Liver Malignancies

Patients meeting the UNOS criteria [(AFP level ≤ 1000 ng/mL and single lesion ≥ 2 cm and ≤ 5 cm, or 2 or 3 lesions ≥ 1 cm and ≤ 3 cm)] should be considered for transplantation (cadaveric or living donation).

The Model for End-Stage Liver Disease (MELD) score is used by UNOS to assess the severity of liver disease and prioritize the allocation of the liver transplants. There are patients whose tumor characteristics are marginally outside of the UNOS guidelines who should be considered for transplant. Furthermore, there are patients who are downstaged to within criteria that can also be considered for transplantation.

The 2019 OPTN and UNOS allocation policy (2019) notes that lesions which are eligible for downstaging protocols must meet one of the following criteria:

1. One lesion greater than 5 cm and less than or equal to 8 cm
2. Two or three lesions that meet all of the following:
 - at least one lesion greater than 3 cm
 - each lesion less than or equal to 5 cm, and
 - a total diameter of all lesions less than or equal to 8 cm
3. Four or five lesions each less than 3 cm, and a total diameter of all lesions less than or equal to 8 cm

For individuals who have meet the downstaging criteria and subsequently undergo local-regional therapy, any residual therapy must meet the definition for T2 lesions in order to be eligible for a standardized MELD or PELD exception.

The Society of Interventional Radiology's Quality Improvement Guidelines for Transarterial Chemoembolization and Embolization of Hepatic Malignancy (Gaba, 2017) states that TACE may be indicated as a downstage to liver transplantation for individuals with liver-dominant hepatic malignancies.

Definitions

Ablation: The destruction of a body part or tissue or its function, which may be achieved by surgery, hormones, drugs, radiofrequency, heat, or other methods.

Adenocarcinoma: Cancer which arises from glandular epithelial cells within internal organs. The majority of breast, lung, esophagus, stomach, colon, rectum, pancreas, prostate, and uterus cancers are classified as adenocarcinomas.

Bridge Therapy: Therapy considered for those who meet transplant criteria, used slow tumor progression in order to decrease the liver transplantation dropout rate.

Federal and State law, as well as contract language including definitions and specific coverage provisions/exclusions, and Medical Policy take precedence over Clinical UM Guidelines and must be considered first in determining eligibility for coverage. The member's contract benefits in effect on the date that services are rendered must be used. Clinical UM Guidelines, which address medical efficacy, should be considered before utilizing medical opinion in adjudication. Medical technology is constantly evolving, and we reserve the right to review and update Clinical UM Guidelines periodically. Clinical UM guidelines are used when the plan performs utilization review for the subject. Due to variances in utilization patterns, each plan may choose whether or not to adopt a particular Clinical UM Guideline. To determine if review is required for this Clinical UM Guideline, please contact the customer service number on the back of the member's card.

No part of this publication may be reproduced, stored in a retrieval system or transmitted, in any form or by any means, electronic, mechanical, photocopying, or otherwise, without permission from the health plan.

© CPT Only – American Medical Association

Healthy Blue is a Medicaid product offered by Missouri Care, Inc., a MO HealthNet Managed Care health plan contracting with the Missouri Department of Social Services. Healthy Blue is administered statewide by Missouri Care, Inc. and administered in the Kansas City service region by Missouri Care, Inc. in cooperation with Blue Cross and Blue Shield of Kansas City. Missouri Care, Inc. and Blue Cross and Blue Shield of Kansas City are both independent licensees of the Blue Cross and Blue Shield Association.

Childs-Turcotte-Pugh (CTP): A scoring system for severity of liver disease and likelihood of survival based on the presence of: degenerative disease of the brain (encephalopathy), the escape or accumulation of fluid in the abdominal cavity (ascites), laboratory measures of various substances in the blood (see table below), and the presence of other co-existing diseases; after calculating the CTP score using a table similar to the one below, candidates can be classified into 1 of 3 categories:

- Childs A (5-6 points): 10 year survival 80-90%
- Childs B (7-9 points): 5 year survival 60-80%
- Childs C (10-15 points): 2 year survival less than 50%

Variable	1 Point	2 Points	3 Points
Encephalopathy	None	Moderate	Severe
Ascites	None	Mild	Moderate
Albumin (mg/dL)	Greater than 3/5	2.8-3.5	Less than 2.8
Prothombin time (International Normalized ratio) prolonged	Less than 4	4-6	Greater than 6
Bilirubin (mg/dL) Primary biliary cirrhosis Cirrhosis/primary Primary sclerosing cholangitis	1-4	4-10	Greater than 10
All other diseases	Less than 2	1-3	Greater than 3

Cancer of the Liver Italian Program (CLIP): A tumor classification system from Italy that includes scoring for 8 clinical parameters for HCC, combining the Child-Turcotte-Pugh scoring system with tumor criteria including tumor morphology, portal invasion, and alpha fetoprotein levels.

Cholangiocarcinoma: A type of cancer developing in cells that line the bile ducts in the liver.

Encapsulated nodules: Any group of abnormal cells confined to a specific area, surrounded by a covering of specialized cells called a capsule.

Extra-hepatic disease: Cancer that is located outside of the liver.

Hepatic metastases: Cancer that has spread from its original location to the liver.

Metastasis: The spread of cancer from one part of the body (the origin of the cancer) to another part of the body. A metastatic tumor contains cells that are like those in the original (primary) tumor and have spread.

Federal and State law, as well as contract language including definitions and specific coverage provisions/exclusions, and Medical Policy take precedence over Clinical UM Guidelines and must be considered first in determining eligibility for coverage. The member's contract benefits in effect on the date that services are rendered must be used. Clinical UM Guidelines, which address medical efficacy, should be considered before utilizing medical opinion in adjudication. Medical technology is constantly evolving, and we reserve the right to review and update Clinical UM Guidelines periodically. Clinical UM guidelines are used when the plan performs utilization review for the subject. Due to variances in utilization patterns, each plan may choose whether or not to adopt a particular Clinical UM Guideline. To determine if review is required for this Clinical UM Guideline, please contact the customer service number on the back of the member's card.

No part of this publication may be reproduced, stored in a retrieval system or transmitted, in any form or by any means, electronic, mechanical, photocopying, or otherwise, without permission from the health plan.

© CPT Only – American Medical Association

Healthy Blue is a Medicaid product offered by Missouri Care, Inc., a MO HealthNet Managed Care health plan contracting with the Missouri Department of Social Services. Healthy Blue is administered statewide by Missouri Care, Inc. and administered in the Kansas City service region by Missouri Care, Inc. in cooperation with Blue Cross and Blue Shield of Kansas City. Missouri Care, Inc. and Blue Cross and Blue Shield of Kansas City are both independent licensees of the Blue Cross and Blue Shield Association.

 Locoregional Techniques for Treating Primary and Metastatic Liver Malignancies

Neuroendocrine tumor: Tumors arising from cells that produce hormones that can cause systemic symptoms such as flushing or wheezing. Examples of neuroendocrine tumors include, but are not limited to carcinoid tumors, islet cell tumors, medullary thyroid carcinoma, and pheochromocytoma.

Palliative treatment: Treatment given for relief of symptoms and pain rather than effecting a cure.

Primary hepatocellular cancer: A cancer that originates within liver cells.

Unresectable: Refers to a tumor that cannot safely be removed surgically due to size or location.

References

Peer Reviewed Publications:

1. Abdelaziz AO, Nabeel MM, Elbaz TM, et al. Microwave ablation versus transarterial chemoembolization in large hepatocellular carcinoma: prospective analysis. *Scand J Gastroenterol.* 2015; 50(4):479-484.
2. Abouchaleh N, Gabr A, Ali R, et al. 90Y Radioembolization for locally advanced hepatocellular carcinoma with portal vein thrombosis: Long-term outcomes in a 185-patient cohort. *J Nucl Med.* 2018; 59(7):1042-1048.
3. Adam R, Hagopian EJ, Linhares M, et al. A comparison of percutaneous cryosurgery and percutaneous radiofrequency for unresectable hepatic malignancies. *Arch Surg.* 2002; 137(2):1332-1339.
4. Agopian VG, Harlander-Locke MP, Ruiz RM, et al. Impact of pretransplant bridging locoregional therapy for patients with hepatocellular carcinoma within Milan criteria undergoing liver transplantation: analysis of 3601 patients from the US Multicenter HCC Transplant Consortium. *Ann Surg.* 2017; 266(3):525-535.
5. Al-Adra DP, Gill RS, Axford SJ, et al. Treatment of unresectable intrahepatic cholangiocarcinoma with yttrium-90 radioembolization: a systematic review and pooled analysis. *Eur J Surg Oncol.* 2015; 41(1):120-127.
6. Albert M, Kiefer MV, Sun W, et al. Chemoembolization of colorectal liver metastases with cisplatin, doxorubicin, mitomycin C, ethiodol, and polyvinyl alcohol. *Cancer.* 2011; 117(2):343-352.
7. Ali R, Riaz A, Gabr A, et al. Clinical outcomes of Y90 radioembolization for recurrent hepatocellular carcinoma following curative resection. *Eur J Nucl Med Mol Imaging.* 2017; 44(13):2195-2202.
8. Aliberti C, Fiorentini G, Muzzio PC, et al. Trans-arterial chemoembolization of metastatic colorectal carcinoma to the liver adopting DC Bead[®], drug-eluting bead loaded with irinotecan: results of a phase II clinical study. *Anticancer Res.* 2011; 31(12):4581-4587.
9. Arora S, Harmath C, Catania R, et al. Hepatocellular carcinoma: metastatic pathways and extra-hepatic findings. *Abdom Radiol (NY).* 2021; 46(8):3698-3707.
10. Artinyan A, Nelson R, Soriano P, et al. Treatment response to transcatheter arterial embolization and chemoembolization in primary and metastatic tumors of the liver. *HPB (Oxford).* 2008; 10(6):396-404.
11. Bacchetti S, Bertozzi S, Londero AP, et al. Surgical treatment and survival in patients with liver metastases from neuroendocrine tumors: a meta-analysis of observational studies. *Int J Hepatol.* 2013; 2013:235040.

Federal and State law, as well as contract language including definitions and specific coverage provisions/exclusions, and Medical Policy take precedence over Clinical UM Guidelines and must be considered first in determining eligibility for coverage. The member's contract benefits in effect on the date that services are rendered must be used. Clinical UM Guidelines, which address medical efficacy, should be considered before utilizing medical opinion in adjudication. Medical technology is constantly evolving, and we reserve the right to review and update Clinical UM Guidelines periodically. Clinical UM guidelines are used when the plan performs utilization review for the subject. Due to variances in utilization patterns, each plan may choose whether or not to adopt a particular Clinical UM Guideline. To determine if review is required for this Clinical UM Guideline, please contact the customer service number on the back of the member's card.

No part of this publication may be reproduced, stored in a retrieval system or transmitted, in any form or by any means, electronic, mechanical, photocopying, or otherwise, without permission from the health plan.

© CPT Only – American Medical Association

Healthy Blue is a Medicaid product offered by Missouri Care, Inc., a MO HealthNet Managed Care health plan contracting with the Missouri Department of Social Services. Healthy Blue is administered statewide by Missouri Care, Inc. and administered in the Kansas City service region by Missouri Care, Inc. in cooperation with Blue Cross and Blue Shield of Kansas City. Missouri Care, Inc. and Blue Cross and Blue Shield of Kansas City are both independent licensees of the Blue Cross and Blue Shield Association.

Locoregional Techniques for Treating Primary and Metastatic Liver Malignancies

12. Baltatzis M, Siriwardena AK. Liver resection for colorectal hepatic metastases after systemic chemotherapy and selective internal radiation therapy with Yttrium-90 microspheres: a systematic review. *Dig Surg*. 2019; 36(4):273-280.
13. Bangash AK, Atassi B, Kaklamani V, et al. 90Y radioembolization of metastatic breast cancer to the liver: toxicity, imaging response, survival. *J Vasc Interv Radiol*. 2007; 18(5):621-628.
14. Bauschke A, Altendorf-Hofmann A, Ardel M, et al. Impact of successful local ablative bridging therapy prior to liver transplantation on long-term survival in patients with hepatocellular carcinoma in cirrhosis. *J Cancer Res Clin Oncol*. 2020; 146(7):1819-1827.
15. Benson AB 3rd, Geschwind JF, Mulcahy MF, et al. Radioembolisation for liver metastases: results from a prospective 151 patient multi-institutional phase II study. *Eur J Cancer*. 2013; 49(15):3122-3130.
16. Berber E, Felsher N, Siperstein AE. Laparoscopic radiofrequency ablation of neuroendocrine liver metastasis. *World J Surg*. 2002; 26(8):985-990.
17. Berber E, Pelley R, Siperstein AE. Predictors of survival after radiofrequency thermal ablation of colorectal cancer metastases to the liver: a prospective study. *J Clin Oncol*. 2005; 23(7):1358-1364.
18. Berber E, Siperstein AE. Laparoscopic radiofrequency ablation of neuroendocrine liver metastases. *Problems in General Surgery*. 2003; 20(3):134-142.
19. Bergenfeldt M, Jensen BV, Skjoldbye B, Nielsen D. Liver resection and local ablation of breast cancer liver metastases – a systematic review. *Eur J Surg Oncol*. 2011; 37(7):549-557.
20. Bester L, Meteling B, Pocock N, et al. Radioembolization versus standard care of hepatic metastases: comparative retrospective cohort study of survival outcomes and adverse events in salvage patients. *J Vasc Interv Radiol*. 2012; 23(1):96-105.
21. Bhagat N, Reyes DK, Lin M, et al. Phase II study of chemoembolization with drug-eluting beads in patients with hepatic neuroendocrine metastases: high incidence of biliary injury. *Cardiovasc Intervent Radiol*. 2013; 36(2):449-459.
22. Bleicher RF, Allegra DP, Nora DT, et al. Radiofrequency ablation in 447 complex unresectable liver tumors: lessons learned. *Ann Surg Oncol*. 2003; 10(1):52-58.
23. Boehm LM, Jayakrishnan TT, Miura JT, et al. Comparative effectiveness of hepatic artery based therapies for unresectable intrahepatic cholangiocarcinoma. *J Surg Oncol*. 2015; 111(2):213-220.
24. Bouchard-Fortier A, Lapointe R, Perreault P, et al. Transcatheter arterial chemoembolization of hepatocellular carcinoma as a bridge to liver transplantation: a retrospective study. *Int J Hepatol*. 2011; 2011:974514.
25. Braat MN, Samim M, van den Bosch MA, Lam MG. The role of (90)Y-radioembolization in downstaging primary and secondary hepatic malignancies: a systematic review. *Clin Transl Imaging*. 2016; 4:283-295.
26. Brown DB, Chapman WC, Cook RD, et al. Chemoembolization of HCC: patient status at presentation and outcome over 15 years at a single center. *AJR Am J Roentgenol*. 2008; 190(3):608-615.
27. Brown KT, Do RK, Gonen M, et al. Randomized trial of hepatic artery embolization for hepatocellular carcinoma using doxorubicin-eluting microspheres compared with embolization with microspheres alone. *J Clin Oncol*. 2016; 34(17):2046-2053.

Federal and State law, as well as contract language including definitions and specific coverage provisions/exclusions, and Medical Policy take precedence over Clinical UM Guidelines and must be considered first in determining eligibility for coverage. The member's contract benefits in effect on the date that services are rendered must be used. Clinical UM Guidelines, which address medical efficacy, should be considered before utilizing medical opinion in adjudication. Medical technology is constantly evolving, and we reserve the right to review and update Clinical UM Guidelines periodically. Clinical UM guidelines are used when the plan performs utilization review for the subject. Due to variances in utilization patterns, each plan may choose whether or not to adopt a particular Clinical UM Guideline. To determine if review is required for this Clinical UM Guideline, please contact the customer service number on the back of the member's card.

No part of this publication may be reproduced, stored in a retrieval system or transmitted, in any form or by any means, electronic, mechanical, photocopying, or otherwise, without permission from the health plan.

© CPT Only – American Medical Association

Healthy Blue is a Medicaid product offered by Missouri Care, Inc., a MO HealthNet Managed Care health plan contracting with the Missouri Department of Social Services. Healthy Blue is administered statewide by Missouri Care, Inc. and administered in the Kansas City service region by Missouri Care, Inc. in cooperation with Blue Cross and Blue Shield of Kansas City. Missouri Care, Inc. and Blue Cross and Blue Shield of Kansas City are both independent licensees of the Blue Cross and Blue Shield Association.

28. Buijs M, Vossen JA, Frangakis C, et al. Nonresectable hepatocellular carcinoma: long-term toxicity in patients treated with transarterial chemoembolization--single-center experience. *Radiology*. 2008; 249(1):346-354.
29. Camma C, Schepis F, Orlando A, et al. Transarterial chemoembolization for unresectable hepatocellular carcinoma: meta-analysis of randomized controlled trials. *Radiology*. 2002; 224(1):47-54.
30. Cao CQ, Yan TD, Bester L, et al. Radioembolization with yttrium microspheres for neuroendocrine tumour liver metastases. *Br J Surg*. 2010; 97(4):537-543.
31. Cassera MA, Hammill CW, Ujiki MB, et al. Surgical management of breast cancer liver metastases. *HPB (Oxford)*. 2011; 13(4):272-278.
32. Chapman WC, Majella Doyle MB, Stuart JE, et al. Outcomes of neoadjuvant transarterial chemoembolization to downstage hepatocellular carcinoma before liver transplantation. *Ann Surg*. 2008; 248(4):617-625.
33. Charalampoudis P, Mantas D, Sotiropoulos GC, et al. Surgery for liver metastases from breast cancer. *Future Oncol*. 2015; 11(10):1519-1530.
34. Chen JX, Rose S, White SB, et al. Embolotherapy for neuroendocrine tumor liver metastases: prognostic factors for hepatic progression-free survival and overall survival. *Cardiovasc Intervent Radiol*. 2017; 40(1):69-80.
35. Cheng BQ, Jia CQ, Liu CT, et al. Chemoembolization combined with radiofrequency ablation for patients with hepatocellular carcinoma larger than 3 cm: a randomized controlled trial. *JAMA*. 2008; 299(14):1669-1677.
36. Cheng HY, Wang X, Chen D, et al. The value and limitation of transcatheter arterial chemoembolization in preventing recurrence of resected hepatocellular carcinoma. *World J Gastroenterol*. 2005a; 11(23):3644-3646.
37. Cheng YF, Huang TL, Chen TY, et al. Impact of pre-operative transarterial embolization on the treatment of hepatocellular carcinoma with liver transplantation. *World J Gastroenterol*. 2005b; 11(10):1433-1438.
38. Christante D, Pommier S, Givi B, Pommier R. Hepatic artery chemoinfusion with chemoembolization for neuroendocrine cancer with progressive hepatic metastases despite octreotide therapy. *Surgery*. 2008; 144(6):885-893; discussion 893-894.
39. Cho YK, Rhim H, Noh S. Radiofrequency ablation versus surgical resection as primary treatment of hepatocellular carcinoma meeting the Milan criteria: a systematic review. *J Gastroenterol Hepatol*. 2011; 26(9):1354-1360.
40. Chong CCN, Lee KF, Cheung SYS, et al. Prospective double-blinded randomized controlled trial of microwave versus radiofrequency ablation for hepatocellular carcinoma (McRFA trial). *HPB (Oxford)*. 2020; 22(8):1121-1127.
41. Chua TC, Liauw W, Saxena A et al. Systematic review of neoadjuvant transarterial chemoembolization for resectable hepatocellular carcinoma. *Liver Transpl*. 2009; 30(2):166-174.
42. Cianni R, Urigo C, Notarianni E, et al. Radioembolisation using yttrium 90 (Y-90) in patients affected by unresectable hepatic metastases. *Radiol Med*. 2010; 115(4):619-633.
43. Dai WC, Cheung TT, Chok KS, et al. Radiofrequency ablation versus transarterial chemoembolization for unresectable solitary hepatocellular carcinomas sized 5-8 cm. *HPB (Oxford)*. 2015; 17(3):226-231.

Federal and State law, as well as contract language including definitions and specific coverage provisions/exclusions, and Medical Policy take precedence over Clinical UM Guidelines and must be considered first in determining eligibility for coverage. The member's contract benefits in effect on the date that services are rendered must be used. Clinical UM Guidelines, which address medical efficacy, should be considered before utilizing medical opinion in adjudication. Medical technology is constantly evolving, and we reserve the right to review and update Clinical UM Guidelines periodically. Clinical UM guidelines are used when the plan performs utilization review for the subject. Due to variances in utilization patterns, each plan may choose whether or not to adopt a particular Clinical UM Guideline. To determine if review is required for this Clinical UM Guideline, please contact the customer service number on the back of the member's card.

No part of this publication may be reproduced, stored in a retrieval system or transmitted, in any form or by any means, electronic, mechanical, photocopying, or otherwise, without permission from the health plan.

© CPT Only – American Medical Association

Healthy Blue is a Medicaid product offered by Missouri Care, Inc., a MO HealthNet Managed Care health plan contracting with the Missouri Department of Social Services. Healthy Blue is administered statewide by Missouri Care, Inc. and administered in the Kansas City service region by Missouri Care, Inc. in cooperation with Blue Cross and Blue Shield of Kansas City. Missouri Care, Inc. and Blue Cross and Blue Shield of Kansas City are both independent licensees of the Blue Cross and Blue Shield Association.

Locoregional Techniques for Treating Primary and Metastatic Liver Malignancies

44. Derek E, Matsuoka L, Alexopoulos S, et al. Combined surgical resection and radiofrequency ablation as treatment for metastatic ocular melanoma. *Surg Today*. 2013; 43(4):367-371.
45. Devcic Z, Rosenberg J, Braat AJ, et al. The efficacy of hepatic 90Y resin radioembolization for metastatic neuroendocrine tumors: a meta-analysis. *J Nucl Med*. 2014; 55(9):1404-1410.
46. Dhanasekaran R, Kooby DA, Staley CA, et al. Comparison of conventional transarterial chemoembolization (TACE) and chemoembolization with doxorubicin drug eluting beads (DEB) for unresectable hepatocellular carcinoma (HCC). *J Surg Oncol*. 2010; 101(6):476-480.
47. Do Minh D, Chapiro J, Gorodetski B, et al. Intra-arterial therapy of neuroendocrine tumour liver metastases: comparing conventional TACE, drug-eluting beads TACE and yttrium-90 radioembolisation as treatment options using a propensity score analysis model. *Eur Radiol*. 2017; 27(12):4995-5005.
48. DuBay D, Sandroussi C, Kachura JR, et al. Radiofrequency ablation of hepatocellular carcinoma as a bridge to liver transplantation. *HPB (Oxford)*. 2011; 13(1):24-32.
49. Dunfee BL, Riaz A, Lewandowski RJ, et al. Yttrium-90 radioembolization for liver malignancies: prognostic factors associated with survival. *J Vasc Interv Radiol*. 2010; 21(1):90-95.
50. Edelhauser G, Schicher N, Berzaczy D, et al. Fotemustine chemoembolization of hepatic metastases from uveal melanoma: a retrospective single-center analysis. *AJR Am J Roentgenol*. 2012; 199(6):1387-1392.
51. Egger ME, Armstrong E, Martin RC 2nd, et al. Transarterial Chemoembolization vs radioembolization for neuroendocrine liver metastases: a multi-institutional analysis. *J Am Coll Surg*. 2020; 230(4):363-370.
52. El Fouly A, Ertle J, El Dorry A, et al. In intermediate stage hepatocellular carcinoma: radioembolization with yttrium 90 or chemoembolization? *Liver Int*. 2015; 35(2):627-635.
53. Facciorusso A, Bellanti F, Villani R, et al. Transarterial chemoembolization vs bland embolization in hepatocellular carcinoma: A meta-analysis of randomized trials. *United European Gastroenterol J*. 2017; 5(4):511-518.
54. Facciorusso A, Di Maso M, Muscatiello N. Drug-eluting beads versus conventional chemoembolization for the treatment of unresectable hepatocellular carcinoma: meta-analysis. *Dig Liver Dis*. 2016a; 48(6):571-577.
55. Facciorusso A, Mariani L, Sposito C, et al. Drug-eluting beads versus conventional chemoembolization for the treatment of unresectable hepatocellular carcinoma. *J Gastroenterol Hepatol*. 2016b; 31(3):645-653.
56. Facciorusso A, Serviddio G, Muscatiello N. Transarterial radioembolization vs chemoembolization for hepatocarcinoma patients: a systematic review and meta-analysis. *World J Hepatol*. 2016; 8(18):770-778.
57. Fairhurst K, Leopardi L, Satyadas T, Maddern G. The safety and effectiveness of liver resection for breast cancer liver metastases: A systematic review. *Breast*. 2016; 30:175-184.
58. Fan H, Zhou C, Yan J, et al. Treatment of solitary hepatocellular carcinoma up to 2 cm: A PRISMA-compliant systematic review and meta-analysis. *Medicine (Baltimore)*. 2020; 99(23):e20321.
59. Feghachi S, Besseling MG, van Santvoort HC, et al. Radiofrequency ablation for unresectable locally advanced pancreatic cancer: a systematic review. *HPB (Oxford)*. 2014; 16(2):119-123.
60. Feng K, Yan J, Li X, et al. A randomized controlled trial of radiofrequency ablation and surgical resection in the treatment of small hepatocellular carcinoma. *J Hepatol*. 2012; 57(4):794-802.

Federal and State law, as well as contract language including definitions and specific coverage provisions/exclusions, and Medical Policy take precedence over Clinical UM Guidelines and must be considered first in determining eligibility for coverage. The member's contract benefits in effect on the date that services are rendered must be used. Clinical UM Guidelines, which address medical efficacy, should be considered before utilizing medical opinion in adjudication. Medical technology is constantly evolving, and we reserve the right to review and update Clinical UM Guidelines periodically. Clinical UM guidelines are used when the plan performs utilization review for the subject. Due to variances in utilization patterns, each plan may choose whether or not to adopt a particular Clinical UM Guideline. To determine if review is required for this Clinical UM Guideline, please contact the customer service number on the back of the member's card.

No part of this publication may be reproduced, stored in a retrieval system or transmitted, in any form or by any means, electronic, mechanical, photocopying, or otherwise, without permission from the health plan.

© CPT Only – American Medical Association

Healthy Blue is a Medicaid product offered by Missouri Care, Inc., a MO HealthNet Managed Care health plan contracting with the Missouri Department of Social Services. Healthy Blue is administered statewide by Missouri Care, Inc. and administered in the Kansas City service region by Missouri Care, Inc. in cooperation with Blue Cross and Blue Shield of Kansas City. Missouri Care, Inc. and Blue Cross and Blue Shield of Kansas City are both independent licensees of the Blue Cross and Blue Shield Association.

61. Feng Q, Chi Y, Liu Y, et al. Efficacy and safety of percutaneous radiofrequency ablation versus surgical resection for small hepatocellular carcinoma: a meta-analysis of 23 studies. *J Cancer Res Clin Oncol*. 2015; 141(1):1-9.
62. Fiorentini G, Aliberti C, Tilli M, et al. Intra-arterial infusion of irinotecan-loaded drug-eluting beads (DEBIRI) versus intravenous therapy (FOLFIRI) for hepatic metastases from colorectal cancer: final results of a phase III study. *Anticancer Res*. 2012; 32(4):1387-1395.
63. Fiorentini G, Aliberti C, Turrisi G, et al. Intraarterial hepatic chemoembolization of liver metastases from colorectal cancer adopting irinotecan-eluting beads: results of a phase II clinical study. *In Vivo*. 2007; 21(6):1085-1091.
64. Fisher RA, Maluf D, Cotterell AH, et al. Non-resective ablative therapy for hepatocellular carcinoma: effectiveness measured by intention-to-treat and dropout from liver transplant waiting list. *Clin Transplant*. 2004; 18(5):502-512.
65. Garin E, Rolland Y, Edeline J, et al. Personalized dosimetry with intensification using 90Y-loaded glass microsphere radioembolization induces prolonged overall survival in hepatocellular carcinoma patients with portal vein thrombosis. *J Nucl Med*. 2015; 56(3):339-346.
66. Georgiades CS, Ramsey DE, Solomon S, et al. New non-surgical therapies in the treatment of hepatocellular carcinomas. *Tech Vasc Intervent Radiol*. 2001; 4(3):193-199.
67. Giorgio A, Di Sarno A, De Stefano G, et al. Percutaneous radiofrequency ablation of hepatocellular carcinoma compared to percutaneous ethanol injection in treatment of cirrhotic patients: an Italian randomized controlled trial. *Anticancer Res*. 2011; 31(6):2291-2295.
68. Giroux MF, Baum RA, Soulen MC. Chemoembolization of liver metastasis from breast carcinoma. *J Vasc Interv Radiol*. 2004; 15(3):289-291.
69. Golfieri R, Giampalma E, Renzulli M, et al.; PRECISION Italia Study Group. Randomised controlled trial of doxorubicin-eluting beads vs conventional chemoembolisation for hepatocellular carcinoma. *Br J Cancer*. 2014; 111(2):255-264.
70. Gomez D, Malik HZ, Al-Mukthar A, et al. Hepatic resection for metastatic gastrointestinal and pancreatic neuroendocrine tumours: outcome and prognostic predictors. *HPB (Oxford)*. 2007; 9(5):345-351.
71. Gonsalves CF, Eschelmann DJ, Adamo RD, et al. A prospective phase II trial of radioembolization for treatment of uveal melanoma hepatic metastasis. *Radiology*. 2019; 293(1):223-231.
72. Gonsalves CF, Eschelmann DJ, Thornburg B, et al. Uveal melanoma metastatic to the liver: Chemoembolization with 1,3-Bis-(2-Chloroethyl)-1-Nitrosourea. *AJR Am J Roentgenol*. 2015; 205(2):429-33.
73. Gootjes EC, van der Stok EP, Buffart TE, et al; ORCHESTRA study group. Safety and feasibility of additional tumor debulking to first-line palliative combination chemotherapy for patients with multiorgan metastatic colorectal cancer. *Oncologist*. 2020; 25(8):e1195-e1201.
74. Gramenzi A, Golfieri R, Mosconi C, et al. Yttrium-90 radioembolization vs sorafenib for intermediate-locally advanced hepatocellular carcinoma: a cohort study with propensity score analysis. *Liver Int*. 2015; 35(3):1036-1047.

Federal and State law, as well as contract language including definitions and specific coverage provisions/exclusions, and Medical Policy take precedence over Clinical UM Guidelines and must be considered first in determining eligibility for coverage. The member's contract benefits in effect on the date that services are rendered must be used. Clinical UM Guidelines, which address medical efficacy, should be considered before utilizing medical opinion in adjudication. Medical technology is constantly evolving, and we reserve the right to review and update Clinical UM Guidelines periodically. Clinical UM guidelines are used when the plan performs utilization review for the subject. Due to variances in utilization patterns, each plan may choose whether or not to adopt a particular Clinical UM Guideline. To determine if review is required for this Clinical UM Guideline, please contact the customer service number on the back of the member's card.

No part of this publication may be reproduced, stored in a retrieval system or transmitted, in any form or by any means, electronic, mechanical, photocopying, or otherwise, without permission from the health plan.

© CPT Only – American Medical Association

Healthy Blue is a Medicaid product offered by Missouri Care, Inc., a MO HealthNet Managed Care health plan contracting with the Missouri Department of Social Services. Healthy Blue is administered statewide by Missouri Care, Inc. and administered in the Kansas City service region by Missouri Care, Inc. in cooperation with Blue Cross and Blue Shield of Kansas City. Missouri Care, Inc. and Blue Cross and Blue Shield of Kansas City are both independent licensees of the Blue Cross and Blue Shield Association.

Locoregional Techniques for Treating Primary and Metastatic Liver Malignancies

75. Gray B, Van Hazel G, Hope M, et al. Randomized trial of SIR-Spheres® plus chemotherapy vs. chemotherapy alone for treating patients with liver metastases from primary large bowel cancer. *Ann Oncol.* 2001; 12(12):1711-1720.
76. Graziadei IW, Sandmueller H, Waldenberger P, et al. Chemoembolization followed by liver transplantation for hepatocellular carcinoma impedes tumor progression while on the waiting list and leads to excellent outcome. *Liver Transpl.* 2003; 9(6):557-563.
77. Grosso M, Vignali C, Quaretti P, et al. Transarterial chemoembolization for hepatocellular carcinoma with drug-eluting microspheres: preliminary results from an Italian multicentre study. *Cardiovasc Intervent Radiol.* 2008; 31(6):1141-1149.
78. Gulec SA, Pennington K, Wheeler J, et al. Yttrium-90 microsphere-selective internal radiation therapy with chemotherapy (chemo-SIRT) for colorectal cancer liver metastases: an in vivo double-arm-controlled phase II trial. *Am J Clin Oncol.* 2013; 36(5):455-460.
79. Gupta S, Yao JC, Ahrar K, et al. Hepatic artery embolization and chemoembolization for treatment of patients with metastatic carcinoid tumors: the M.D. Anderson experience. *Cancer J.* 2003; 9(4):261-267.
80. Hayashi PH, Ludkowski M, Forman LM, et al. Hepatic artery chemoembolization for hepatocellular carcinoma in patients listed for liver transplantation. *Am J Transplant.* 2004; 4(5):782-787.
81. Heckman J, Devera M, Marsh J, et al. Bridging locoregional therapy for hepatocellular carcinoma prior to liver transplantation. *Ann Surg Oncol.* 2008; 15(11):3169-3177.
82. Hendlisz A, Van den Eynde M, et al. Phase III trial comparing protracted intravenous fluorouracil infusion alone or with yttrium-90 resin microspheres radioembolization for liver-limited metastatic colorectal cancer refractory to standard chemotherapy. *J Clin Oncol.* 2010; 28(23):3687-3694.
83. Hendricks-Wenger A, Weber P, Simon A, et al. Histotripsy for the treatment of cholangiocarcinoma liver tumors: in vivo feasibility and ex vivo dosimetry study. *IEEE Trans Ultrason Ferroelectr Freq Control.* 2021; 68(9):2953-2964.
84. Henn AR, Levine EA, McNulty W, Zagoria RJ. Percutaneous radiofrequency ablation of hepatic metastases for symptomatic relief of neuroendocrine syndromes. *AJR Am J Roentgenol.* 2003; 181(4):1005-1010.
85. Herba MJ, Thirlwell MP. Radioembolization for hepatic metastases. *Semin Oncol.* 2002; 29(2):152-159.
86. Hong K, McBride JD, Georgiades CS, et al. Salvage therapy for liver-dominant colorectal metastatic adenocarcinoma: comparison between transcatheter arterial chemoembolization versus yttrium-90 radioembolization. *J Vasc Interv Radiol.* 2009; 20(3):360-367.
87. Hui Y, Ruihua T, Jing L, et al. Meta-Analysis of doxorubicin-eluting beads via transcatheter arterial chemoembolization in the treatment of unresectable hepatocellular carcinoma. *Hepatogastroenterology.* 2015; 62(140):1002-1006.
88. Huppert PE, Fierlbeck G, Pereira P et al. Transarterial chemoembolization of liver metastases in patients with uveal melanoma. *Eur J Radiol.* 2010; 74(3):e38-e44.
89. Hur S, Chung JW, Kim HC, et al. Survival outcomes and prognostic factors of transcatheter arterial chemoembolization for hepatic neuroendocrine metastases. *J Vasc Interv Radiol.* 2013; 24(7):947-956.

Federal and State law, as well as contract language including definitions and specific coverage provisions/exclusions, and Medical Policy take precedence over Clinical UM Guidelines and must be considered first in determining eligibility for coverage. The member's contract benefits in effect on the date that services are rendered must be used. Clinical UM Guidelines, which address medical efficacy, should be considered before utilizing medical opinion in adjudication. Medical technology is constantly evolving, and we reserve the right to review and update Clinical UM Guidelines periodically. Clinical UM guidelines are used when the plan performs utilization review for the subject. Due to variances in utilization patterns, each plan may choose whether or not to adopt a particular Clinical UM Guideline. To determine if review is required for this Clinical UM Guideline, please contact the customer service number on the back of the member's card.

No part of this publication may be reproduced, stored in a retrieval system or transmitted, in any form or by any means, electronic, mechanical, photocopying, or otherwise, without permission from the health plan.

© CPT Only – American Medical Association

Healthy Blue is a Medicaid product offered by Missouri Care, Inc., a MO HealthNet Managed Care health plan contracting with the Missouri Department of Social Services. Healthy Blue is administered statewide by Missouri Care, Inc. and administered in the Kansas City service region by Missouri Care, Inc. in cooperation with Blue Cross and Blue Shield of Kansas City. Missouri Care, Inc. and Blue Cross and Blue Shield of Kansas City are both independent licensees of the Blue Cross and Blue Shield Association.

Locoregional Techniques for Treating Primary and Metastatic Liver Malignancies

90. Jakobs TF, Hoffmann RT, Fischer T, et al. Radioembolization in patients with hepatic metastases from breast cancer. *J Vasc Interv Radiol*. 2008; 19(5):683-690.
91. Jia Z, Wang W. Yttrium-90 radioembolization for unresectable metastatic neuroendocrine liver tumor: A systematic review. *Eur J Radiol*. 2018; 100:23-29.
92. Kallini JR, Gabr A, Thorlund K et al. Comparison of the adverse event profile of TheraSphere® with SIR-Spheres® for the treatment of unresectable hepatocellular carcinoma: a systematic review. *Cardiovasc Intervent Radiol*. 2017; 40(7):1033-1043.
93. Kamal A, Elmoety AAA, Rostom YAM, et al. Percutaneous radiofrequency versus microwave ablation for management of hepatocellular carcinoma: a randomized controlled trial. *J Gastrointest Oncol*. 2019; 10(3):562-571.
94. Karanicolas P, Beecroft JR, Cosby R, et al; Gastrointestinal Disease Site Group. Regional therapies for colorectal liver metastases: Systematic review and clinical practice guideline. *Clin Colorectal Cancer*. 2021; 20(1):20-28.
95. Katsanos K, Kitrou P, Spiliopoulos S, et al. Comparative effectiveness of different transarterial embolization therapies alone or in combination with local ablative or adjuvant systemic treatments for unresectable hepatocellular carcinoma: A network meta-analysis of randomized controlled trials. *PLoS One*. 2017 Sep 21;12(9):e0184597.
96. Kemeny MM, Adack C, Gray B, et al. Combined-modality treatment for resectable colorectal carcinoma to the liver: surgical resection of hepatic metastases in combination with continuous infusion of chemotherapy – an intergroup study. *J Clin Oncol*. 2002; 20(6):1499-1505.
97. Kennedy AS, Dezarn WA, McNeillie P, et al. Radioembolization for unresectable neuroendocrine hepatic metastases using resin 90Y-microspheres: early results in 148 patients. *Am J Clin Oncol*. 2008; 31(3):271-279.
98. Kettenbach J, Stadler A, Katzler IV, et al. Drug-loaded microspheres for the treatment of liver cancer: review of current results. *Cardiovasc Intervent Radiol*. 2008; 31(3):468-476.
99. Kiefer MV, Albert M, McNally M, et al. Chemoembolization of intrahepatic cholangiocarcinoma with cisplatin, doxorubicin, mitomycin C, ethiodol, and polyvinyl alcohol: a 2-center study. *Cancer*. 2011; 117(7):1498-1505.
100. Kim DY, Park BJ, Kim YH, Radioembolization with yttrium-90 resin microspheres in hepatocellular carcinoma: a multicenter prospective study. *Am J Clin Oncol*. 2015; 38(5):495-501.
101. Kim JH, Yoon HK, Sung KB, et al. Transcatheter arterial chemoembolization or chemoinfusion for unresectable intrahepatic cholangiocarcinoma: clinical efficacy and factors influencing outcomes. *Cancer*. 2008; 113(7):1614-1622.
102. King J, Quinn R, Glenn DM, et al. Radioembolization with selective internal radiation microspheres for neuroendocrine liver metastases. *Cancer*. 2008; 113(5):921-929.
103. Kivelä T, Eskelin S, Kujala E. Metastatic uveal melanoma. *Int Ophthalmol Clin*. 2006; 46(1):133-149.
104. Kloeckner R, Weinmann A, Prinz F, et al. Conventional transarterial chemoembolization versus drug-eluting bead transarterial chemoembolization for the treatment of hepatocellular carcinoma. *BMC Cancer*. 2015; 15:465.

Federal and State law, as well as contract language including definitions and specific coverage provisions/exclusions, and Medical Policy take precedence over Clinical UM Guidelines and must be considered first in determining eligibility for coverage. The member's contract benefits in effect on the date that services are rendered must be used. Clinical UM Guidelines, which address medical efficacy, should be considered before utilizing medical opinion in adjudication. Medical technology is constantly evolving, and we reserve the right to review and update Clinical UM Guidelines periodically. Clinical UM guidelines are used when the plan performs utilization review for the subject. Due to variances in utilization patterns, each plan may choose whether or not to adopt a particular Clinical UM Guideline. To determine if review is required for this Clinical UM Guideline, please contact the customer service number on the back of the member's card.

No part of this publication may be reproduced, stored in a retrieval system or transmitted, in any form or by any means, electronic, mechanical, photocopying, or otherwise, without permission from the health plan.

© CPT Only – American Medical Association

Healthy Blue is a Medicaid product offered by Missouri Care, Inc., a MO HealthNet Managed Care health plan contracting with the Missouri Department of Social Services. Healthy Blue is administered statewide by Missouri Care, Inc. and administered in the Kansas City service region by Missouri Care, Inc. in cooperation with Blue Cross and Blue Shield of Kansas City. Missouri Care, Inc. and Blue Cross and Blue Shield of Kansas City are both independent licensees of the Blue Cross and Blue Shield Association.

Locoregional Techniques for Treating Primary and Metastatic Liver Malignancies

105. Knüppel M, Kubicka S, Vogel A, et al. Combination of conservative and interventional therapy strategies for intra- and extrahepatic cholangiocellular carcinoma: a retrospective survival analysis. *Gastroenterol Res Pract*. 2012; 2012:190708.
106. Kolligs FT, Bilbao JI, Jakobs T, et al. Pilot randomized trial of selective internal radiation therapy vs. chemoembolization in unresectable hepatocellular carcinoma. *Liver Int*. 2015; 35(6):1715-1721.
107. Kuei A, Saab S, Cho SK, et al. Effects of yttrium-90 selective internal radiation therapy on non-conventional liver tumors. *World J Gastroenterol*. 2015; 21(27):8271-8283.
108. Kulik LM, Atassi B, van Holsbeeck L, et al. Yttrium-90 microspheres (TheraSphere) treatment of unresectable hepatocellular carcinoma: downstaging to resection, RFA and bridge to transplantation. *J Surg Oncol*. 2006; 94(7):572-586.
109. Kulik L, Heimbach JK, Zaiem F, et al. Therapies for patients with hepatocellular carcinoma awaiting liver transplantation: A systematic review and meta-analysis. *Hepatology*. 2018; 67(1):381-400.
110. Kümler I, Parner VK, Tuxen MK, et al. Clinical outcome of percutaneous RF-ablation of non-operable patients with liver metastasis from breast cancer. *Radiol Med*. 2015; 120(6):536-541.
111. Kwok PC, Leung KC, Cheung MT, et al. Survival benefit of radioembolization for inoperable hepatocellular carcinoma using yttrium-90 microspheres. *J Gastroenterol Hepatol*. 2014; 29(11):1897-1904.
112. Ikeda M, Okada S, Ueno H, et al. Radiofrequency ablation and percutaneous ethanol injection in patients with small hepatocellular carcinoma: a comparative study. *Jpn J Clin Oncol*. 2001; 31(7):322-326.
113. Lammer J, Malagari K, Vogl T, et al. Prospective randomized study of doxorubicin-eluting-bead embolization in the treatment of HCC: results of the PRECISION V study. *Cardiovasc Intervent Radiol*. 2010; 33(1):41-52.
114. Lance C, McLennan G, Obuchowski N, et al. Comparative analysis of the safety and efficacy of transcatheter arterial chemoembolization and yttrium-90 radioembolization in patients with unresectable hepatocellular carcinoma. *J Vasc Interv Radiol*. 2011; 22(12):1697-1705.
115. Lanza E, Muglia R, Bolengo I, et al. Survival analysis of 230 patients with unresectable hepatocellular carcinoma treated with bland transarterial embolization. *PLoS One*. 2020; 15(1):e0227711.
116. Lau WY, Lai EC. Hepatocellular carcinoma: current management and recent advances. *Hepatobiliary Pancreat Dis Int*. 2008; 7(3):237-257.
117. Lau WY, Yu SC, Lai EC, Leung TW. Transarterial chemoembolization for hepatocellular carcinoma. *J Am Coll Surg*. 2006; 202(1):155-168.
118. Lee M, Chung JW, Lee KH, et al. Korean multicenter registry of transcatheter arterial chemoembolization with drug-eluting embolic agents for nodular hepatocellular carcinomas: six-month outcome analysis. *J Vasc Interv Radiol*. 2017; 28(4):502-512.
119. Lee S, Kim KW, Song GW, et al. The Real Impact of Bridging or Downstaging on Survival Outcomes after Liver Transplantation for Hepatocellular Carcinoma. *Liver Cancer*. 2020; 9(6):721-733.
120. Lee MW, Raman SS, Asvadi NH, et al. Radiofrequency ablation of hepatocellular carcinoma as bridge therapy to liver transplantation: A 10-year intention-to-treat analysis. *Hepatology*. 2017; 65(6):1979-1990.

Federal and State law, as well as contract language including definitions and specific coverage provisions/exclusions, and Medical Policy take precedence over Clinical UM Guidelines and must be considered first in determining eligibility for coverage. The member's contract benefits in effect on the date that services are rendered must be used. Clinical UM Guidelines, which address medical efficacy, should be considered before utilizing medical opinion in adjudication. Medical technology is constantly evolving, and we reserve the right to review and update Clinical UM Guidelines periodically. Clinical UM guidelines are used when the plan performs utilization review for the subject. Due to variances in utilization patterns, each plan may choose whether or not to adopt a particular Clinical UM Guideline. To determine if review is required for this Clinical UM Guideline, please contact the customer service number on the back of the member's card.

No part of this publication may be reproduced, stored in a retrieval system or transmitted, in any form or by any means, electronic, mechanical, photocopying, or otherwise, without permission from the health plan.

© CPT Only – American Medical Association

Healthy Blue is a Medicaid product offered by Missouri Care, Inc., a MO HealthNet Managed Care health plan contracting with the Missouri Department of Social Services. Healthy Blue is administered statewide by Missouri Care, Inc. and administered in the Kansas City service region by Missouri Care, Inc. in cooperation with Blue Cross and Blue Shield of Kansas City. Missouri Care, Inc. and Blue Cross and Blue Shield of Kansas City are both independent licensees of the Blue Cross and Blue Shield Association.

Locoregional Techniques for Treating Primary and Metastatic Liver Malignancies

121. Lencioni RA, Allgaier HP, Cioni D, et al. Small hepatocellular carcinoma in cirrhosis: randomized comparison of radiofrequency thermal ablation versus percutaneous ethanol injection. *Radiology*. 2003; 228(1):235-240.
122. Lentz RW, Messersmith WA. Transarterial radioembolization in patients with unresectable colorectal cancer liver metastases. *J Clin Oncol*. 2021; 39(35):3887-3889.
123. Lermite E, Lebigot J, Oberti F, et al. Radiofrequency thermal ablation of liver carcinoma. Prospective study of 82 lesions. *Gastroenterol Clin Biol*. 2006; 30(1):130-135.
124. Lesurtel M, Nagorney DM, Mazzaferro V, et al. When should a liver resection be performed in patients with liver metastases from neuroendocrine tumours? A systematic review with practice recommendations. *HPB (Oxford)*. 2015; 17(1):17-22.
125. Lewandowski RJ, Kulik LM, Riaz A, et al. A comparative analysis of transarterial downstaging for hepatocellular carcinoma: chemoembolization versus radioembolization. *Am J Transplant*. 2009; 9(8):1920-1928.
126. Lewandowski RJ, Memon K, Mulcahy MF, et al. Twelve-year experience of radioembolization for colorectal hepatic metastases in 214 patients: survival by era and chemotherapy. *Eur J Nucl Med Mol Imaging*. 2014; 41(10):1861-1869.
127. Li XP, Meng ZQ, Guo WJ, Li J. Treatment for liver metastases from breast cancer: results and prognostic factors. *World J Gastroenterol*. 2005; 11(24):3782-3787.
128. Li L, Zhang J, Liu X, et al. Clinical outcomes of radiofrequency ablation and surgical resection for small hepatocellular carcinoma: a meta-analysis. *J Gastroenterol Hepatol*. 2012; 27(1):51-58.
129. Liapi E, Geschwind JF. Transcatheter and ablative therapeutic approaches for solid malignancies. *J Clin Oncol*. 2007; 25(8):978-986.
130. Lim L, Gibbs P, Yip D, et al. Prospective study of treatment with selective internal radiation therapy spheres in patients with unresectable primary or secondary hepatic malignancies. *Intern Med J*. 2005; 35(4):222-227.
131. Liu H, Wang ZG, Fu SY, et al. Randomized clinical trial of chemoembolization plus radiofrequency ablation versus partial hepatectomy for hepatocellular carcinoma within the Milan criteria. *Br J Surg*. 2016; 103(4):348-356.
132. Liu W, Bahig H, Palma DA. Oligometastases: Emerging evidence. *J Clin Oncol*. 2022; 40(36):4250-4260.
133. Livraghi T, Goldberg SN, Lazzaroni S, et al. Hepatocellular carcinoma: radio-frequency ablation of medium and large lesions. *Radiology*. 2000; 214(3):761-768.
134. Livraghi T, Goldberg SN, Lazzaroni S, et al. Small hepatocellular carcinoma: treatment with radiofrequency ablation versus ethanol injection. *Radiology*. 1999; 210(3):655-661.
135. Llovet JM. Evidence-based medicine in the treatment of hepatocellular cancer. *J Gastroenterol Hepatol*. 2002a; 17 Suppl 3:S428-S433.
136. Llovet JM, Bruix J. Systemic review of randomized trials for unresectable hepatocellular carcinoma: chemoembolization improves survival. *Hepatology*. 2003; 37(2):429-442.
137. Llovet JM, Di Bisceglie AM, Bruix J, et al. Panel of Experts in HCC-Design Clinical Trials. Design and endpoints of clinical trials in hepatocellular carcinoma. *J Natl Cancer Inst*. 2008; 100(10):698-711.

Federal and State law, as well as contract language including definitions and specific coverage provisions/exclusions, and Medical Policy take precedence over Clinical UM Guidelines and must be considered first in determining eligibility for coverage. The member's contract benefits in effect on the date that services are rendered must be used. Clinical UM Guidelines, which address medical efficacy, should be considered before utilizing medical opinion in adjudication. Medical technology is constantly evolving, and we reserve the right to review and update Clinical UM Guidelines periodically. Clinical UM guidelines are used when the plan performs utilization review for the subject. Due to variances in utilization patterns, each plan may choose whether or not to adopt a particular Clinical UM Guideline. To determine if review is required for this Clinical UM Guideline, please contact the customer service number on the back of the member's card.

No part of this publication may be reproduced, stored in a retrieval system or transmitted, in any form or by any means, electronic, mechanical, photocopying, or otherwise, without permission from the health plan.

© CPT Only – American Medical Association

Healthy Blue is a Medicaid product offered by Missouri Care, Inc., a MO HealthNet Managed Care health plan contracting with the Missouri Department of Social Services. Healthy Blue is administered statewide by Missouri Care, Inc. and administered in the Kansas City service region by Missouri Care, Inc. in cooperation with Blue Cross and Blue Shield of Kansas City. Missouri Care, Inc. and Blue Cross and Blue Shield of Kansas City are both independent licensees of the Blue Cross and Blue Shield Association.

Locoregional Techniques for Treating Primary and Metastatic Liver Malignancies

138. Llovet JM, Fuster J, Bruix J. The Barcelona approach: diagnosis, staging, and treatment of hepatocellular carcinoma. *Liver Transpl.* 2004; 10(2 Suppl 1):S115-S120.
139. Llovet JM, Real ML, Montaña X, et al. Arterial embolization or chemoembolization versus symptomatic treatment in patients with unresectable hepatocellular carcinoma: a randomized controlled trial. *Lancet.* 2002b; 359(9319):1734-1739.
140. Lo C, Ngan H, Tso W, et al. Randomized controlled trial of transarterial lipiodol chemoembolization for unresectable hepatocellular carcinoma. *Hepatology.* 2002; 35(5):1164-1171.
141. Lobo L, Yakoub D, Picado O, et al. Unresectable hepatocellular carcinoma: radioembolization versus chemoembolization: a systematic review and meta-analysis. *Cardiovasc Intervent Radiol.* 2016; 39(11):1580-1588.
142. Lu DS, Yu NC, Raman SS, et al. Radiofrequency ablation of hepatocellular carcinoma: treatment success as defined by histologic examination of the explanted liver. *Radiology.* 2005; 234(3):954-960.
143. Ludwig JM, Zhang D, Xing M, Kim HS. Meta-analysis: adjusted indirect comparison of drug-eluting bead transarterial chemoembolization versus (90)Y-radioembolization for hepatocellular carcinoma. *Eur Radiol.* 2017; 27(5):2031-2041.
144. Majno P, Giostra E, Mentha G. Management of hepatocellular carcinoma on the waiting list before liver transplantation: time for controlled trials? *Liver Transpl.* 2007; 13(11 Suppl 2):S27-S35.
145. Malagari K, Pomoni M, Kelekis A, et al. Prospective randomized comparison of chemoembolization with doxorubicin-eluting beads and bland embolization with Bead Block for hepatocellular carcinoma. *Cardiovasc Intervent Radiol.* 2010; 33(3):541-551.
146. Malagari K, Pomoni M, Spyridopoulos TN, et al. Safety profile of sequential transcatheter chemoembolization with DC Bead: results of 237 hepatocellular carcinoma (HCC) patients. *Cardiovasc Intervent Radiol.* 2011; 34:774-785.
147. Maluccio MA, Covey AM, Porat LB, et al. Transcatheter arterial embolization with only particles for the treatment of unresectable hepatocellular carcinoma. *J Vasc Interv Radiol.* 2008; 19(6):862-869.
148. Maluccio MA, Covey AM, Schubert J, et al. Treatment of metastatic sarcoma to the liver with bland embolization. *Cancer.* 2006; 107(7):1617-1623.
149. Marelli L, Stigliano R, Triantos C, et al. Transarterial therapy for hepatocellular carcinoma: which technique is more effective? A systematic review of cohort and randomized studies. *Cardiovasc Intervent Radiol.* 2007; 30(1):6-25.
150. Martin RC, Howard J, Tomalty D, et al. Toxicity of irinotecan-eluting beads in the treatment of hepatic malignancies: results of a multi-institutional registry. *Cardiovasc Intervent Radiol.* 2010; 33(5):960-966.
151. Martin RC, Joshi J, Robbins K, et al. Hepatic intra-arterial injection of drug-eluting bead, irinotecan (DEBIRI) in unresectable colorectal liver metastases refractory to systemic chemotherapy: results of multi-institutional study. *Ann Surg Oncol.* 2011; 18(1):192-198.
152. Martin RC, Robbins K, Tomalty D, et al. Transarterial chemoembolisation (TACE) using irinotecan-loaded beads for the treatment of unresectable metastases to the liver in patients with colorectal cancer: an interim report. *World J Surg Oncol.* 2009; 7:80.

Federal and State law, as well as contract language including definitions and specific coverage provisions/exclusions, and Medical Policy take precedence over Clinical UM Guidelines and must be considered first in determining eligibility for coverage. The member's contract benefits in effect on the date that services are rendered must be used. Clinical UM Guidelines, which address medical efficacy, should be considered before utilizing medical opinion in adjudication. Medical technology is constantly evolving, and we reserve the right to review and update Clinical UM Guidelines periodically. Clinical UM guidelines are used when the plan performs utilization review for the subject. Due to variances in utilization patterns, each plan may choose whether or not to adopt a particular Clinical UM Guideline. To determine if review is required for this Clinical UM Guideline, please contact the customer service number on the back of the member's card.

No part of this publication may be reproduced, stored in a retrieval system or transmitted, in any form or by any means, electronic, mechanical, photocopying, or otherwise, without permission from the health plan.

© CPT Only – American Medical Association

Healthy Blue is a Medicaid product offered by Missouri Care, Inc., a MO HealthNet Managed Care health plan contracting with the Missouri Department of Social Services. Healthy Blue is administered statewide by Missouri Care, Inc. and administered in the Kansas City service region by Missouri Care, Inc. in cooperation with Blue Cross and Blue Shield of Kansas City. Missouri Care, Inc. and Blue Cross and Blue Shield of Kansas City are both independent licensees of the Blue Cross and Blue Shield Association.

Locoregional Techniques for Treating Primary and Metastatic Liver Malignancies

153. Martin RC, Scoggins CR, McMasters KM. Safety and efficacy of microwave ablation of hepatic tumors: a prospective review of a 5-year experience. *Ann Surg Oncol*. 2010; 17(1):171-178.
154. Martin RC 2nd, Scoggins CR, Schreeder M, et al. Randomized controlled trial of irinotecan drug-eluting beads with simultaneous FOLFOX and bevacizumab for patients with unresectable colorectal liver-limited metastasis. *Cancer*. 2015; 121(20):3649-3658.
155. Mavligit GM, Charnsangavej C, Carrasco CH, et al. Regression of ocular melanoma metastatic to the liver after hepatic arterial chemoembolization with cisplatin and polyvinyl sponge. *JAMA*. 1988; 260(7):974-976.
156. Mazzaglia PJ, Berber E, Milas M, Siperstein AE. Laparoscopic radiofrequency ablation of neuroendocrine liver metastases: a 10-year experience evaluating predictors of survival. *Surgery*. 2007; 142(1):10-19.
157. McDevitt JL, Alian A, Kapoor B, et al. Single-center comparison of overall survival and toxicities in patients with infiltrative hepatocellular carcinoma treated with Yttrium-90 radioembolization or drug-eluting embolic transarterial chemoembolization. *J Vasc Interv Radiol*. 2017; 28(10):1371-1377.
158. Meloni MF, Andreano A, Laeseke PF, et al. Breast cancer liver metastases: US-guided percutaneous radiofrequency ablation--intermediate and long-term survival rates. *Radiology*. 2009; 253(3):861-869.
159. Merli M, Nicolini G, Gentili F, et al. Predictive factors of outcome after liver transplantation in patients with cirrhosis and hepatocellular carcinoma. *Transplant Proc*. 2005; 37(6):2535-2540.
160. Molinari M, Kachura JR, Dixon E, et al. Transarterial chemoembolisation for advanced hepatocellular carcinoma: results from a North American Cancer Centre. *Clin Oncol (R Coll Radiol)*. 2006; 18(9):684-692.
161. Moreno-Luna LE, Yang JD, Sanchez W, et al. Efficacy and safety of transarterial radioembolization versus chemoembolization in patients with hepatocellular carcinoma. *Cardiovasc Intervent Radiol*. 2013; 36(3):714-723.
162. Morimoto M, Numata K, Sugimori K, et al. Successful initial ablation therapy contributes to survival in patients with hepatocellular carcinoma. *World J Gastroenterol*. 2007; 13(7):1003-1009.
163. Moroz P, Anderson JE, Van Hazel G, et al. Effect of selective internal radiation therapy and hepatic arterial chemotherapy on normal liver volume and spleen volume. *J Surg Oncol*. 2001; 78(4):248-252.
164. Mulcahy MF, Lewandowski RJ, Ibrahim SM, et al. Radioembolization of colorectal hepatic metastases using yttrium-90 microspheres. *Cancer*. 2009; 115(9):1849-1858.
165. Mulcahy MF, Mahvash A, Pracht M, et al; EPOCH Investigators. Radioembolization with chemotherapy for colorectal liver metastases: A randomized, open-label, international, multicenter, phase III trial. *J Clin Oncol*. 2021; 39(35):3897-3907.
166. Mulier S, Ni Y, Jamart J, et al. Local recurrence after hepatic radiofrequency coagulation: multivariate meta-analysis and review of contributing factors. *Ann Surg*. 2005; 242(2):158-171.
167. Nace GW, Steel JL, Amesur N, et al. Yttrium-90 radioembolization for colorectal cancer liver metastases: a single institution experience. *Int J Surg Oncol*. 2011; 2011:571261.
168. Nicolini D, Svegliati-Baroni G, et al. Doxorubicin-eluting bead vs conventional transcatheter arterial chemoembolization for hepatocellular carcinoma before liver transplantation. *World J Gastroenterol*. 2013; 19(34):5622-5632.

Federal and State law, as well as contract language including definitions and specific coverage provisions/exclusions, and Medical Policy take precedence over Clinical UM Guidelines and must be considered first in determining eligibility for coverage. The member's contract benefits in effect on the date that services are rendered must be used. Clinical UM Guidelines, which address medical efficacy, should be considered before utilizing medical opinion in adjudication. Medical technology is constantly evolving, and we reserve the right to review and update Clinical UM Guidelines periodically. Clinical UM guidelines are used when the plan performs utilization review for the subject. Due to variances in utilization patterns, each plan may choose whether or not to adopt a particular Clinical UM Guideline. To determine if review is required for this Clinical UM Guideline, please contact the customer service number on the back of the member's card.

No part of this publication may be reproduced, stored in a retrieval system or transmitted, in any form or by any means, electronic, mechanical, photocopying, or otherwise, without permission from the health plan.

© CPT Only – American Medical Association

Healthy Blue is a Medicaid product offered by Missouri Care, Inc., a MO HealthNet Managed Care health plan contracting with the Missouri Department of Social Services. Healthy Blue is administered statewide by Missouri Care, Inc. and administered in the Kansas City service region by Missouri Care, Inc. in cooperation with Blue Cross and Blue Shield of Kansas City. Missouri Care, Inc. and Blue Cross and Blue Shield of Kansas City are both independent licensees of the Blue Cross and Blue Shield Association.

Locoregional Techniques for Treating Primary and Metastatic Liver Malignancies

169. Obed A, Behan A, Pullmann K, et al. Patients without hepatocellular carcinoma progression after transarterial chemoembolization benefit from liver transplantation. *World J Gastroenterol*. 2007; 13(5):761-767.
170. Park SY, Kim JH, Yoon HJ, et al. Transarterial chemoembolization versus supportive therapy in the palliative treatment of unresectable intrahepatic cholangiocarcinoma. *Clin Radiol*. 2011; 66(4):322-328.
171. Patel K, Sullivan K, Berd D, et al. Chemoembolization of the hepatic artery with BCNU for metastatic uveal melanoma: results of a phase II study. *Melanoma Res*. 2005; (4):297-304.
172. Pawlik TM, Reyes DK, Cosgrove D, et al. Phase II trial of sorafenib combined with concurrent transarterial chemoembolization with drug-eluting beads for hepatocellular carcinoma. *J Clin Oncol*. 2011; 29(30):3960-3977. Erratum in: *J Clin Oncol*. 2011; 29(34):4596-4598.
173. Pawlik T, Schulick RD, Choti M. Expanding criteria for resectability of colorectal liver metastases. *Oncologist*. 2008; 13(1):51-64.
174. Peng ZW, Liu FR, Ye S, et al. Radiofrequency ablation versus open hepatic resection for elderly patients (> 65 years) with very early or early hepatocellular carcinoma. *Cancer*. 2013; 119(21):3812-3820.
175. Peng ZW, Zhang YJ, Chen MS, et al. Radiofrequency ablation as first-line treatment for small solitary hepatocellular carcinoma: long-term results. *Eur J Surg Oncol*. 2010; 36(11):1054-1060.
176. Peng ZW, Zhang YJ, Liang HH, et al. Recurrent hepatocellular carcinoma treated with sequential transcatheter arterial chemoembolization and RF ablation versus RF ablation alone: a prospective randomized trial. *Radiology*. 2010; 262(2):689-700.
177. Petrelli F, Coiu A, Cabiddu M, et al. Hepatic resection for gastric cancer liver metastases: a systematic review and meta-analysis. *J Surg Oncol*. 2015; 111(8):1021-1027.
178. Petruzzi NJ, Frangos AJ, Fenkel JM, et al. Single-center comparison of three chemoembolization regimens for hepatocellular carcinoma. *J Vasc Interv Radiol*. 2013; 24(2):266-273.
179. Poggi G, Quaretti P, Minoia C, et al. Transhepatic arterial chemoembolization with oxaliplatin-eluting microspheres (OEM-TACE) for unresectable hepatic tumors. *Anticancer Res*. 2008; 28(6B):3835-3842.
180. Ponti A, Denys A, Digkila A, et al. First-line selective internal radiation therapy in patients with uveal melanoma metastatic to the liver. *J Nucl Med*. 2020; 61(3):350-356.
181. Poon RT, Tso WK, Pang RW, et al. A phase I/II trial of chemoembolization for hepatocellular carcinoma using a novel intra-arterial drug-eluting bead. *Clin Gastroenterol Hepatol*. 2007; 5(9):1100-1108.
182. Prajapati HJ, Dhanasekaran R, El-Rayes BF, et al. Safety and efficacy of doxorubicin drug-eluting bead transarterial chemoembolization in patients with advanced hepatocellular carcinoma. *J Vasc Interv Radiol*. 2013; 24(3):307-315.
183. Pulitanò C, Bodingbauer M, Aldrighetti L, et al. Liver resection for colorectal metastases in presence of extrahepatic disease: results from an international multi-institutional analysis. *Ann Surg Oncol*. 2011; 18(5):1380-1388.
184. Ramsey DE, Geschwind JF. New interventions for liver tumors. *Semin Roentgenol*. 2002; 37(4):303-311.
185. Ramsey DE, Kernagis LY, Soulen MC, Geschwind JF. Chemoembolization of hepatocellular carcinoma. *J Vasc Interv Radiol*. 2002; 13(Pt 2):S211-S221.

Federal and State law, as well as contract language including definitions and specific coverage provisions/exclusions, and Medical Policy take precedence over Clinical UM Guidelines and must be considered first in determining eligibility for coverage. The member's contract benefits in effect on the date that services are rendered must be used. Clinical UM Guidelines, which address medical efficacy, should be considered before utilizing medical opinion in adjudication. Medical technology is constantly evolving, and we reserve the right to review and update Clinical UM Guidelines periodically. Clinical UM guidelines are used when the plan performs utilization review for the subject. Due to variances in utilization patterns, each plan may choose whether or not to adopt a particular Clinical UM Guideline. To determine if review is required for this Clinical UM Guideline, please contact the customer service number on the back of the member's card.

No part of this publication may be reproduced, stored in a retrieval system or transmitted, in any form or by any means, electronic, mechanical, photocopying, or otherwise, without permission from the health plan.

© CPT Only – American Medical Association

Healthy Blue is a Medicaid product offered by Missouri Care, Inc., a MO HealthNet Managed Care health plan contracting with the Missouri Department of Social Services. Healthy Blue is administered statewide by Missouri Care, Inc. and administered in the Kansas City service region by Missouri Care, Inc. in cooperation with Blue Cross and Blue Shield of Kansas City. Missouri Care, Inc. and Blue Cross and Blue Shield of Kansas City are both independent licensees of the Blue Cross and Blue Shield Association.

Locoregional Techniques for Treating Primary and Metastatic Liver Malignancies

186. Rantala ES, Hernberg M, Kivelä TT. Overall survival after treatment for metastatic uveal melanoma: a systematic review and meta-analysis. *Melanoma Res.* 2019; 29(6):561-568.
187. Ravaoli M, Grazi GL, Piscaglia F, et al. Liver transplantation for hepatocellular carcinoma: results of down-staging in patients initially outside the Milan selection criteria. *Am J Transplant.* 2008; 8(12):2547-2557.
188. Reyes DK, Vossen JA, Kamel IR, et al. Single-center phase II trial of transarterial chemoembolization with drug-eluting beads for patients with unresectable hepatocellular carcinoma: initial experience in the United States. *Cancer J.* 2009; 15(6):526-532.
189. Rhee TK, Lewandowski RJ, Liu DM, et al. 90Y Radioembolization for metastatic neuroendocrine liver tumors: preliminary results from a multi-institutional experience. *Ann Surg.* 2008; 247(6):1029-1035.
190. Richardson AJ, Laurence JM, Lam VW. Transarterial chemoembolization with irinotecan beads in the treatment of colorectal liver metastases: systematic review. *J Vasc Interv Radiol.* 2013; 24(8):1209-1217.
191. Roayaie S, Frischer J, Emre SH, et al. Long-term results with multimodal adjuvant therapy and liver transplantation for the treatment of hepatocellular carcinomas larger than 5 centimeters. *Ann Surg.* 2002; 235(4):533-539.
192. Roche A, Girish BV, de Baere T, et al. Trans-catheter arterial chemoembolization as first-line treatment for hepatic metastases from endocrine tumors. *Eur Radiol.* 2003; 13(1):136-140.
193. Rognoni C, Ciani O, Sommariva S, et al. Trans-arterial radioembolization in intermediate-advanced hepatocellular carcinoma: systematic review and meta-analyses. *Oncotarget.* 2016; 7(44):72343-72355.
194. Ruutuainen AT, Soulen MC, Tuite CM, et al. Chemoembolization and bland embolization of neuroendocrine tumor metastases to the liver. *J Vasc Interv Radiol.* 2007; 18(7):847-855.
195. Sacco R, Bargellini I, Bertini M, et al. Conventional versus doxorubicin-eluting bead transarterial chemoembolization for hepatocellular carcinoma. *J Vasc Interv Radiol.* 2011; 22(11):1545-1552.
196. Sadick M, Haas S, Loehr M, et al. Application of DC beads in hepatocellular carcinoma: clinical and radiological results of a drug delivery device for transcatheter superselective arterial embolization. *Onkologie.* 2010; 33(1-2):31-37.
197. Salem R, Gordon AC, Mouli S, et al. Y90 radioembolization significantly prolongs time to progression compared with chemoembolization in patients with hepatocellular carcinoma. *Gastroenterology.* 2016; 151(6):1155-1163.e2.
198. Salem R, Lewandowski RJ, Kulik L, et al. Radioembolization results in longer time-to-progression and reduced toxicity compared with chemoembolization in patients with hepatocellular carcinoma. *Gastroenterology.* 2011; 140(2):497-507.
199. Salem R, Lewandowski RJ, Mulcahy MF, et al. Radioembolization for hepatocellular carcinoma using Yttrium-90 microspheres: a comprehensive report of long-term outcomes. *Gastroenterology.* 2010; 138(1):52-64.
200. Sangro B, Carpanese L, Cianni R, et al.; European Network on Radioembolization with Yttrium-90 Resin Microspheres (ENRY). Survival after yttrium-90 resin microsphere radioembolization of hepatocellular carcinoma across Barcelona clinic liver cancer stages: a European evaluation. *Hepatology.* 2011; 54(3):868-878.

Federal and State law, as well as contract language including definitions and specific coverage provisions/exclusions, and Medical Policy take precedence over Clinical UM Guidelines and must be considered first in determining eligibility for coverage. The member's contract benefits in effect on the date that services are rendered must be used. Clinical UM Guidelines, which address medical efficacy, should be considered before utilizing medical opinion in adjudication. Medical technology is constantly evolving, and we reserve the right to review and update Clinical UM Guidelines periodically. Clinical UM guidelines are used when the plan performs utilization review for the subject. Due to variances in utilization patterns, each plan may choose whether or not to adopt a particular Clinical UM Guideline. To determine if review is required for this Clinical UM Guideline, please contact the customer service number on the back of the member's card.

No part of this publication may be reproduced, stored in a retrieval system or transmitted, in any form or by any means, electronic, mechanical, photocopying, or otherwise, without permission from the health plan.

© CPT Only – American Medical Association

Healthy Blue is a Medicaid product offered by Missouri Care, Inc., a MO HealthNet Managed Care health plan contracting with the Missouri Department of Social Services. Healthy Blue is administered statewide by Missouri Care, Inc. and administered in the Kansas City service region by Missouri Care, Inc. in cooperation with Blue Cross and Blue Shield of Kansas City. Missouri Care, Inc. and Blue Cross and Blue Shield of Kansas City are both independent licensees of the Blue Cross and Blue Shield Association.

Locoregional Techniques for Treating Primary and Metastatic Liver Malignancies

201. Sangro B, Martínez-Urbistondo D, Bester L, et al. Prevention and treatment of complications of selective internal radiation therapy: Expert guidance and systematic review. *Hepatology*. 2017; 66(3):969-982.
202. Salman HS, Cynamon J, Jagust M, et al. Randomized phase II trial of embolization therapy versus chemoembolization therapy in previously treated patients with colorectal carcinoma metastatic to the liver. *Clin Colorectal Cancer*. 2002; 2(3):173-179.
203. Sarmiento JM, Heywood G, Rubin J, et al. Surgical treatment of neuroendocrine metastases to the liver: a plea for resection to increase survival. *J Am Coll Surg*. 2003; 197(1):29-37.
204. Sato T, Eschelmann DJ, Gonsalves CF, et al. Immunoembolization of malignant liver tumors, including uveal melanoma, using granulocyte-macrophage colony-stimulating factor. *J Clin Oncol*. 2008; 26(33):5436-5442.
205. Sato KT, Lewandowski RJ, Mulcahy MF, et al. Unresectable chemorefractory liver metastases: radioembolization with 90Y microspheres--safety, efficacy, and survival. *Radiology*. 2008; 247(2):507-515.
206. Saxena A, Bester L, Shan L, et al. A systematic review on the safety and efficacy of yttrium-90 radioembolization for unresectable, chemorefractory colorectal cancer liver metastases. *J Cancer Res Clin Oncol*. 2014; 140(4):537-547.
207. Saxena A, Chua TC, Bester L, et al. Factors predicting response and survival after yttrium-90 radioembolization of unresectable neuroendocrine tumor liver metastases: a critical appraisal of 48 cases. *Ann Surg*. 2010; 251(5):910-916.
208. Saxena A, Chua TC, Chu F, et al. Optimizing the surgical effort in patients with advanced neuroendocrine neoplasm hepatic metastases: a critical analysis of 40 patients treated by hepatic resection and cryoablation. *Am J Clin Oncol*. 2012; 35(5):439-445.
209. Saxena A, Chua TC, Chu RC, et al. Impact of treatment modality and number of lesions on recurrence and survival outcomes after treatment of colorectal cancer liver metastases. *J Gastrointest Oncol*. 2014; 5(1):46-56.
210. Saxena A, Meteling B, Kapoor J, et al. Yttrium-90 radioembolization is a safe and effective treatment for unresectable hepatocellular carcinoma: a single centre experience of 45 consecutive patients. *Int J Surg*. 2014; 12(12):1403-1408.
211. Sauer P, Kraus TW, Schemmer P, et al. Liver transplantation for hepatocellular carcinoma: is there evidence for expanding the selection criteria? *Transplantation*. 2005; 80(1 Suppl):S105-S108.
212. Seidensticker M, Garlipp B, Scholz S, et al. Locally ablative treatment of breast cancer liver metastases: identification of factors influencing survival (the Mammary Cancer Microtherapy and Interventional Approaches (MAMMA MIA) study). *BMC Cancer*. 2015; 15:517.
213. Shady W, Petre EN, Do KG, et al. Percutaneous microwave versus radiofrequency ablation of colorectal liver metastases: ablation with clear margins (A0) provides the best Local tumor control. *J Vasc Interv Radiol*. 2018; 29(2):268-275.
214. Shen A, Zhang H, Tang C, et al. Systematic review of radiofrequency ablation versus percutaneous ethanol injection for small hepatocellular carcinoma up to 3 cm. *J Gastroenterol Hepatol*. 2013; 28(5):793-800.
215. Siebenhüner AR, Güller U, Warschkow R. Population-based SEER analysis of survival in colorectal cancer patients with or without resection of lung and liver metastases. *BMC Cancer*. 2020; 20(1):246.

Federal and State law, as well as contract language including definitions and specific coverage provisions/exclusions, and Medical Policy take precedence over Clinical UM Guidelines and must be considered first in determining eligibility for coverage. The member's contract benefits in effect on the date that services are rendered must be used. Clinical UM Guidelines, which address medical efficacy, should be considered before utilizing medical opinion in adjudication. Medical technology is constantly evolving, and we reserve the right to review and update Clinical UM Guidelines periodically. Clinical UM guidelines are used when the plan performs utilization review for the subject. Due to variances in utilization patterns, each plan may choose whether or not to adopt a particular Clinical UM Guideline. To determine if review is required for this Clinical UM Guideline, please contact the customer service number on the back of the member's card.

No part of this publication may be reproduced, stored in a retrieval system or transmitted, in any form or by any means, electronic, mechanical, photocopying, or otherwise, without permission from the health plan.

© CPT Only – American Medical Association

Healthy Blue is a Medicaid product offered by Missouri Care, Inc., a MO HealthNet Managed Care health plan contracting with the Missouri Department of Social Services. Healthy Blue is administered statewide by Missouri Care, Inc. and administered in the Kansas City service region by Missouri Care, Inc. in cooperation with Blue Cross and Blue Shield of Kansas City. Missouri Care, Inc. and Blue Cross and Blue Shield of Kansas City are both independent licensees of the Blue Cross and Blue Shield Association.

Locoregional Techniques for Treating Primary and Metastatic Liver Malignancies

216. Siperstein AE, Berber E. Cryoablation, percutaneous alcohol injection, and radiofrequency ablation for treatment of neuroendocrine liver metastases. *World J Surg*. 2001; 25(6):693-696.
217. Song do S, Choi JY, Yoo SH, et al. DC Bead transarterial chemoembolization is effective in hepatocellular carcinoma refractory to conventional transarterial chemoembolization: a pilot study. *Gut Liver*. 2013; 7(1):89-95.
218. Song JE, Jung KS, Kim DY, et al. Transarterial radioembolization versus concurrent chemoradiation therapy for locally advanced hepatocellular carcinoma: A Propensity Score Matching Analysis. *Int J Radiat Oncol Biol Phys*. 2017; 99(2):396-406.
219. Song MJ, Chun HJ, Song do S, et al. Comparative study between doxorubicin-eluting beads and conventional transarterial chemoembolization for treatment of hepatocellular carcinoma. *J Hepatol*. 2012; 57(6):1244-1250.
220. Steel J, Baum A, Carr B. Quality of life in patients diagnosed with primary hepatocellular carcinoma: hepatic arterial infusion of cisplatin versus 90-yttrium microspheres (Therasphere) *Psycho-oncology*. 2004; 13(2):73-79.
221. Stewart CL, Warner S, Ito K, et al. Cytoreduction for colorectal metastases: liver, lung, peritoneum, lymph nodes, bone, brain. When does it palliate, prolong survival, and potentially cure? *Curr Probl Surg*. 2018; 55(9):330-379.
222. Stippel DL, Brochhagen HG, Arenja M, et al. Variability of size and shape of necrosis induced by radiofrequency ablation in human livers: a volumetric evaluation. *Ann Surg Oncol*. 2004; 11(4):420-425.
223. Takemura N, Saiura A, Koga R, et al. Long-term results of hepatic resection for non-colorectal, non-neuroendocrine liver metastasis. *Hepatogastroenterology*. 2013; 60(127):1705-1712.
224. Taniguchi M, Kim SR, Imoto S, et al. Long-term outcome of percutaneous ethanol injection therapy for minimum-sized hepatocellular carcinoma. *World J Gastroenterol*. 2008; 14(13):1997-2002.
225. Tateishi R, Shiina S, Teratani, et al. Percutaneous radiofrequency ablation for hepatocellular carcinoma: an analysis of 1000 cases. *Cancer*. 2005; 103(6):1201-1209.
226. Tovoli F, Negrini G, Bolondi L. Comparative analysis of current guidelines for the treatment of hepatocellular carcinoma. *Hepat Oncol*. 2016; 3(2):119-136.
227. Trinchet JC, Ganne-Carrie N, Beaugrand M. Review article: intra-arterial treatments in patients with hepatocellular carcinoma. *Aliment Pharmacol Ther*. 2003; 17(Suppl 2):111-118.
228. Tulokas S, Mäenpää H, Peltola E, et al. Selective internal radiation therapy (SIRT) as treatment for hepatic metastases of uveal melanoma: a Finnish nation-wide retrospective experience. *Acta Oncol*. 2018; 57(10):1373-1380.
229. Uggeri F, Pinotti E, Sandini M, et al. Prognostic Factors Affecting Long-Term Survival after Resection for Noncolorectal, Nonneuroendocrine, and Nonsarcoma Liver Metastases. *Gastroenterol Res Pract*. 2017; 2017:5184146.
230. Uggeri F, Ronchi PA, Goffredo P, et al. Metastatic liver disease from non-colorectal, non-neuroendocrine, non-sarcoma cancers: a systematic review. *World J Surg Oncol*. 2015; 13:191.

Federal and State law, as well as contract language including definitions and specific coverage provisions/exclusions, and Medical Policy take precedence over Clinical UM Guidelines and must be considered first in determining eligibility for coverage. The member's contract benefits in effect on the date that services are rendered must be used. Clinical UM Guidelines, which address medical efficacy, should be considered before utilizing medical opinion in adjudication. Medical technology is constantly evolving, and we reserve the right to review and update Clinical UM Guidelines periodically. Clinical UM guidelines are used when the plan performs utilization review for the subject. Due to variances in utilization patterns, each plan may choose whether or not to adopt a particular Clinical UM Guideline. To determine if review is required for this Clinical UM Guideline, please contact the customer service number on the back of the member's card.

No part of this publication may be reproduced, stored in a retrieval system or transmitted, in any form or by any means, electronic, mechanical, photocopying, or otherwise, without permission from the health plan.

© CPT Only – American Medical Association

Healthy Blue is a Medicaid product offered by Missouri Care, Inc., a MO HealthNet Managed Care health plan contracting with the Missouri Department of Social Services. Healthy Blue is administered statewide by Missouri Care, Inc. and administered in the Kansas City service region by Missouri Care, Inc. in cooperation with Blue Cross and Blue Shield of Kansas City. Missouri Care, Inc. and Blue Cross and Blue Shield of Kansas City are both independent licensees of the Blue Cross and Blue Shield Association.

231. Valsecchi ME, Terai M, Eschelmann DJ, et al. Double-blinded, randomized phase II study using embolization with or without granulocyte-macrophage colony-stimulating factor in uveal melanoma with hepatic metastases. *J Vasc Interv Radiol*. 2015; 26(4):523-532.e2
232. Van Hazel G, Pavlakis N, Goldstein D, et al. Treatment of fluorouracil-refractory patients with liver metastases from colorectal cancer by using Yttrium-90 resin microspheres plus concomitant systemic irinotecan chemotherapy. *J Clin Oncol*. 2009; 27(25):4089-4095.
233. van Malenstein H, Maleux G, Vandecaveye V, et al. A randomized phase II study of drug-eluting beads versus transarterial chemoembolization for unresectable hepatocellular carcinoma. *Onkologie*. 2011; 34(7):368-376.
234. Varela M, Real MI, Burrell M, et al. Chemoembolization of hepatocellular carcinoma with drug eluting beads: efficacy and doxorubicin pharmacokinetics. *J Hepatol*. 2007; 46(3):474-481.
235. Veltri A, Gazzera C, Calandri M, et al. Percutaneous treatment of hepatocellular carcinoma exceeding 3 cm: combined therapy or microwave ablation? Preliminary results. *Radiol Med*. 2015; 120(12):1177-1183.
236. Vente MA, Wondergem M, van der Tweel I, et al. Yttrium-90 microsphere radioembolization for the treatment of liver malignancies: a structured meta-analysis. *Eur Radiol*. 2009; 19(4):951-959.
237. Vidal-Jove J, Serres X, Vlaisavljevich E, et al. First-in-man histotripsy of hepatic tumors: the THERESA trial, a feasibility study. *Int J Hyperthermia*. 2022; 39(1):1115-1123.
238. Vietti Violi N, Duran R, et al. Efficacy of microwave ablation versus radiofrequency ablation for the treatment of hepatocellular carcinoma in patients with chronic liver disease: a randomised controlled phase 2 trial. *Lancet Gastroenterol Hepatol*. 2018; 3(5):317-325.
239. Vilgrain V, Pereira H, Assenat E, et al. Efficacy and safety of selective internal radiotherapy with yttrium-90 resin microspheres compared with sorafenib in locally advanced and inoperable hepatocellular carcinoma (SARAH): an open-label randomised controlled phase 3 trial. *Lancet Oncol*. 2017; 18(12):1624-1636.
240. Virani S, Michaelson JS, Hutter MM, et al. Morbidity and mortality after liver resection: results of the patient safety in surgery study. *J Am Coll Surg*. 2007; 204(6):1284-1292.
241. Vogl TJ, Gruber T, Balzer JO, et al. Repeated transarterial chemoembolization in the treatment of liver metastases of colorectal cancer: prospective study. *Radiology*. 2009; 250(1):281-289.
242. Vogl TJ, Lammer J, Lencioni R, et al. Liver, gastrointestinal, and cardiac toxicity in intermediate hepatocellular carcinoma treated with PRECISION TACE with drug-eluting beads: results from the PRECISION V randomized trial. *AJR Am J Roentgenol*. 2011; 197(4):W562-W570.
243. Vogl TJ, Naguib NN, Lehnert T, et al. Initial experience with repetitive transarterial chemoembolization (TACE) as a third line treatment of ovarian cancer metastasis to the liver: indications, outcomes and role in patient's management. *Gynecol Oncol*. 2012; 124(2):225-229.
244. Vogl TJ, Naguib NN, Nour-Eldin NE, et al. Transarterial chemoembolization (TACE) with mitomycin C and gemcitabine for liver metastases in breast cancer. *Eur Radiol*. 2010; 20(1):173-180.
245. Vouche M, Habib A, Ward TJ, et al. Unresectable solitary hepatocellular carcinoma not amenable to radiofrequency ablation: multicenter radiology-pathology correlation and survival of radiation segmentectomy. *Hepatology*. 2014; 60(1):192-201.

Federal and State law, as well as contract language including definitions and specific coverage provisions/exclusions, and Medical Policy take precedence over Clinical UM Guidelines and must be considered first in determining eligibility for coverage. The member's contract benefits in effect on the date that services are rendered must be used. Clinical UM Guidelines, which address medical efficacy, should be considered before utilizing medical opinion in adjudication. Medical technology is constantly evolving, and we reserve the right to review and update Clinical UM Guidelines periodically. Clinical UM guidelines are used when the plan performs utilization review for the subject. Due to variances in utilization patterns, each plan may choose whether or not to adopt a particular Clinical UM Guideline. To determine if review is required for this Clinical UM Guideline, please contact the customer service number on the back of the member's card.

No part of this publication may be reproduced, stored in a retrieval system or transmitted, in any form or by any means, electronic, mechanical, photocopying, or otherwise, without permission from the health plan.

© CPT Only – American Medical Association

Healthy Blue is a Medicaid product offered by Missouri Care, Inc., a MO HealthNet Managed Care health plan contracting with the Missouri Department of Social Services. Healthy Blue is administered statewide by Missouri Care, Inc. and administered in the Kansas City service region by Missouri Care, Inc. in cooperation with Blue Cross and Blue Shield of Kansas City. Missouri Care, Inc. and Blue Cross and Blue Shield of Kansas City are both independent licensees of the Blue Cross and Blue Shield Association.

Locoregional Techniques for Treating Primary and Metastatic Liver Malignancies

246. Wang H, Cao C, Wei X, et al. A comparison between drug-eluting bead-transarterial chemoembolization and conventional transarterial chemoembolization in patients with hepatocellular carcinoma: A meta-analysis of six randomized controlled trials. *J Cancer Res Ther.* 2020;16(2):243-249.
247. Wasan HS, Gibbs P, Sharma NK, et al. First-line selective internal radiotherapy plus chemotherapy versus chemotherapy alone in patients with liver metastases from colorectal cancer (FOXFIRE, SIRFLOX, and FOXFIRE-Global): a combined analysis of three multicentre, randomised, phase 3 trials. *Lancet Oncol.* 2017; 18(9):1159-1171.
248. Wei CY, Chen PC, Chau GY, et al. Comparison of prognosis between surgical resection and transarterial chemoembolization for patients with solitary huge hepatocellular carcinoma. *Ann Transl Med.* 2020; 8(5):238.
249. Woodall EC, Scoggins CR, Ellis SF, et al. Is selective internal radioembolization safe and effective for patients with inoperable hepatocellular carcinoma and venous thrombosis? *J Am Coll Surg.* 2009; 208(3):375-382.
250. Xiang J, Liu M, Lu R, et al. Magnetic resonance-guided ablation of liver tumors: A systematic review and pooled analysis. *J Cancer Res Ther.* 2020; 16(5):1093-1099.
251. Xiao YB, Zhang B, Wu YL. Radiofrequency ablation versus hepatic resection for breast cancer liver metastasis: a systematic review and meta-analysis. *J Zhejiang Univ Sci B.* 2018; 19(11):829-843.
252. Xie ZB, Wang XB, Peng YC, et al. Systematic review comparing the safety and efficacy of conventional and drug-eluting bead transarterial chemoembolization for inoperable hepatocellular carcinoma. *Hepatol Res.* 2015; 45(2):190-200.
253. Xu Z, Hall TL, Vlasisavljevich E, Lee FT Jr. Histotripsy: the first noninvasive, non-ionizing, non-thermal ablation technique based on ultrasound. *Int J Hyperthermia.* 2021; 38(1):561-575.
254. Yamakado K, Nakatsuka A, Takaki H, et al. Early-stage hepatocellular carcinoma: radiofrequency ablation combined with chemoembolization versus hepatectomy. *Radiology.* 2008; 247(1):260-266.
255. Yamamoto A, Chervoneva I, Sullivan KL, et al. High-dose immunoembolization: survival benefit in patients with hepatic metastases from uveal melanoma. *Radiology.* 2009; 252(1):290-298.
256. Yamashiki N, Tateishi R, Yoshida H, et al. Ablation therapy in containing extension of hepatocellular carcinoma: a simulative analysis of dropout from the waiting list for liver transplantation. *Liver Transpl.* 2005; 11(5):508-514.
257. Yang Y, Si T. Yttrium-90 transarterial radioembolization versus conventional transarterial chemoembolization for patients with hepatocellular carcinoma: a systematic review and meta-analysis. *Cancer Biol Med.* 2018; 15(3):299-310.
258. Yao FY, Bass NM, Nikolai B, et al. A follow-up analysis of the pattern and predictors of dropout from the waiting list for liver transplantation in patients with hepatocellular carcinoma: implications for the current organ allocation policy. *Liver Transpl.* 2003; 9(7):684-692.
259. Yao FY, Kerlan RK Jr, Hirose R, et al. Excellent outcome following down-staging of hepatocellular carcinoma prior to liver transplantation: an intention-to-treat analysis. *Hepatology.* 2008; 48(3):819-827
260. Yao FY, Kinkhabwala M, LaBerge JM, et al. The impact of pre-operative locoregional therapy on outcome after liver transplantation for hepatocellular carcinoma. *Am J Transplant.* 2005; 5(4 Pt 1):795-804.

Federal and State law, as well as contract language including definitions and specific coverage provisions/exclusions, and Medical Policy take precedence over Clinical UM Guidelines and must be considered first in determining eligibility for coverage. The member's contract benefits in effect on the date that services are rendered must be used. Clinical UM Guidelines, which address medical efficacy, should be considered before utilizing medical opinion in adjudication. Medical technology is constantly evolving, and we reserve the right to review and update Clinical UM Guidelines periodically. Clinical UM guidelines are used when the plan performs utilization review for the subject. Due to variances in utilization patterns, each plan may choose whether or not to adopt a particular Clinical UM Guideline. To determine if review is required for this Clinical UM Guideline, please contact the customer service number on the back of the member's card.

No part of this publication may be reproduced, stored in a retrieval system or transmitted, in any form or by any means, electronic, mechanical, photocopying, or otherwise, without permission from the health plan.

© CPT Only – American Medical Association

Healthy Blue is a Medicaid product offered by Missouri Care, Inc., a MO HealthNet Managed Care health plan contracting with the Missouri Department of Social Services. Healthy Blue is administered statewide by Missouri Care, Inc. and administered in the Kansas City service region by Missouri Care, Inc. in cooperation with Blue Cross and Blue Shield of Kansas City. Missouri Care, Inc. and Blue Cross and Blue Shield of Kansas City are both independent licensees of the Blue Cross and Blue Shield Association.

Locoregional Techniques for Treating Primary and Metastatic Liver Malignancies

261. Yao FY, Mehta N, Flemming J, et al. Downstaging of hepatocellular cancer before liver transplant: long-term outcome compared to tumors within Milan criteria. *Hepatology*. 2015; 61(6):1968-1677.
262. Yu J, Yu XL, Han ZY, et al. Percutaneous cooled-probe microwave versus radiofrequency ablation in early-stage hepatocellular carcinoma: a phase III randomised controlled trial. *Gut*. 2017 Jun;66(6):1172-1173.
263. Yue YY, Zhou WL. Hepatic resection is associated with improved long-term survival compared to radio-frequency ablation in patients with multifocal hepatocellular carcinoma. *Front Oncol*. 2020; 10:110.
264. Young JY, Rhee TK, Atassi B, et al. Radiation dose limits and liver toxicities resulting from multiple yttrium-90 radioembolization treatments for hepatocellular carcinoma. *J Vasc Interv Radiol*. 2007; 18(11):1375-1382.
265. Yun BL, Lee JM, Baek JH, et al. Radiofrequency ablation for treating liver metastases from a non-colorectal origin. *Korean J Radiol*. 2011; 12(5):579-587.
266. Zacharias AJ, Jayakrishnan TT, Rajeev R, et al. Comparative effectiveness of hepatic artery based therapies for unresectable colorectal liver metastases: a meta-analysis. *PLoS One*. 2015; 10(10):e0139940.
267. Zhang X, Chen B, Hu S, et al. Microwave ablation with cooled-tip electrode for liver cancer: an analysis of 160 cases. *Hepatogastroenterology*. 2008; 55(88):2184-2187.
268. Zhang CS, Zhang JL, Li XH, et al. Is radiofrequency ablation equal to surgical re-resection for recurrent hepatocellular carcinoma meeting the Milan criteria? A meta-analysis. *J BUON*. 2015; 20(1):223-230.
269. Zhong JH, Rodríguez AC, Ke Y, et al. Hepatic resection as a safe and effective treatment for hepatocellular carcinoma involving a single large tumor, multiple tumors, or macrovascular invasion. *Medicine (Baltimore)*. 2015; 94(3):e396.
270. Zhang Y, Li Y, Ji H, et al. Transarterial Y90 radioembolization versus chemoembolization for patients with hepatocellular carcinoma: A meta-analysis. *Biosci Trends*. 2015; 9(5):289-298.
271. Zhou Y, Zhang X, Wu L, et al. Meta-analysis: preoperative transcatheter arterial chemoembolization does not improve prognosis of patient with resectable hepatocellular carcinoma. *BMC Gastroenterol*. 2013; 13:51.

Government Agency, Medical Society, and Other Authoritative Publications:

1. Abdel-Rahman OM, Elsayed Z. Yttrium-90 microsphere radioembolisation for unresectable hepatocellular carcinoma. *Cochrane Database Syst Rev*. 2016;(2):CD011313.
2. American College of Gastroenterology. ACG Clinical Guideline: The Diagnosis and Management of Focal Liver Lesions (2014). Available at: https://journals.lww.com/ajg/Fulltext/2014/09000/ACG_Clinical_Guideline_The_Diagnosis_and.7.aspx#pdf-link. Accessed on May 18, 2023.
3. American College of Radiology. ACR Appropriateness Criteria® Management of Liver Cancer. Last review date 2022. Available at: <https://acsearch.acr.org/docs/69379/Narrative/>. Accessed on May 18, 2023.
4. American College of Radiology (ACR), American Brachytherapy Society (ABS), American College of Nuclear Medicine (ACNM), American Society for Radiation Oncology (ASTRO), Society of Interventional Radiology (SIR), and Society of Nuclear Medicine and Molecular Imaging (SNMMI). ACR–ABS–ACNM–ASTRO–SIR–SNMMI Practice parameter for selective Internal Radiation Therapy (SIRT) or

Federal and State law, as well as contract language including definitions and specific coverage provisions/exclusions, and Medical Policy take precedence over Clinical UM Guidelines and must be considered first in determining eligibility for coverage. The member's contract benefits in effect on the date that services are rendered must be used. Clinical UM Guidelines, which address medical efficacy, should be considered before utilizing medical opinion in adjudication. Medical technology is constantly evolving, and we reserve the right to review and update Clinical UM Guidelines periodically. Clinical UM guidelines are used when the plan performs utilization review for the subject. Due to variances in utilization patterns, each plan may choose whether or not to adopt a particular Clinical UM Guideline. To determine if review is required for this Clinical UM Guideline, please contact the customer service number on the back of the member's card.

No part of this publication may be reproduced, stored in a retrieval system or transmitted, in any form or by any means, electronic, mechanical, photocopying, or otherwise, without permission from the health plan.

© CPT Only – American Medical Association

Healthy Blue is a Medicaid product offered by Missouri Care, Inc., a MO HealthNet Managed Care health plan contracting with the Missouri Department of Social Services. Healthy Blue is administered statewide by Missouri Care, Inc. and administered in the Kansas City service region by Missouri Care, Inc. in cooperation with Blue Cross and Blue Shield of Kansas City. Missouri Care, Inc. and Blue Cross and Blue Shield of Kansas City are both independent licensees of the Blue Cross and Blue Shield Association.

- Radioembolization for Treatment of Liver Malignancies. Revised 2019. Available at: <https://www.acr.org/-/media/ACR/Files/Practice-Parameters/RMBD.pdf>. Accessed on May 18, 2023.
5. Bala MM, Riemsma RP, Wolff R, Kleijnen J. Cryotherapy for liver metastases. *Cochrane Database Syst Rev*. 2013;(6):CD009058.
 6. Bala MM, Riemsma RP, Wolff R, Kleijnen J. Microwave coagulation for liver metastases. *Cochrane Database Syst Rev*. 2013;(10):CD010163.
 7. Brown DB, Geschwind JF, Soulen M, et al. Society of Interventional Radiology (SIR) position statement on chemoembolization of hepatic malignancies. *J Vasc Interv Radiol*. 2006; 17(2):217-223.
 8. Brown DB, Nikolic B, Covey AM, et al. Society of Interventional Radiology Standards of Practice Committee. Quality improvement guidelines for transhepatic arterial chemoembolization, embolization, and chemotherapeutic infusion for hepatic malignancy. *J Vasc Interv Radiol*. 2012; 23(3):287-294.
 9. Bruix J, Sherman M. American Association for the Study of Liver Disease (AASLD) Practice Guideline: Management of hepatocellular carcinoma. *Hepatology*. 2005; 42(5):1208-1235.
 10. Bruix J, Sherman M. American Association for the Study of Liver Disease (AASLD) Practice Guideline: Management of hepatocellular carcinoma: an update. *Hepatology*. 2011; 53(3):1020-1058.
 11. Charnsangavej C, Clary B, Fong, Y, et al. Selection of patients for resection of hepatic colorectal metastases: expert consensus statement. *Ann Surg Oncol*. 2006; 13(10):1261-1268.
 12. Cirocchi R, Trastulli S, Boselli C, et al. Radiofrequency ablation in the treatment of liver metastases from colorectal cancer. *Cochrane Database Syst Rev*. 2012;(6):CD006317.
 13. Expert Panel on Interventional Radiology; Knavel Koepsel EM, Smolock AR, et al. ACR Appropriateness Criteria® Management of Liver Cancer: 2022 Update. *J Am Coll Radiol*. 2022; 19(11S):S390-S408.
 14. Fedorowicz Z, Lodge M, Al-Asfoor A, Carter B. Resection versus no intervention or other surgical interventions for colorectal cancer liver metastases. *Cochrane Database Syst Rev*. 2008;(2):CD006039.
 15. Gaba RC, Lokken P, Hickey RM, et al. Society of Interventional Radiology. Quality improvement guidelines for transarterial chemoembolization and embolization of hepatic malignancy. 2017; (9):1210-1223.
 16. Gervais DA, Goldberg SN, Brown DB, et al. Society of Interventional Radiology position statement on percutaneous radiofrequency ablation for the treatment of liver tumors. *J Vasc Interv Radiol*. 2009; 20(7 Suppl):S342-S347.
 17. Gurusamy KS, Ramamoorthy R, Sharma D, Davidson BR. Liver resection versus other treatments for neuroendocrine tumours in patients with resectable liver metastases. *Cochrane Database Syst Rev*. 2009;(2):CD007060.
 18. Heimbach JK, Kulik LM, Finn RS, et al. AASLD guidelines for the treatment of hepatocellular carcinoma. *Hepatology*. 2018; 67(1):358-380.
 19. Hickey R, Lewandowski RJ, Prudhomme T, et al. 90Y radioembolization of colorectal hepatic metastases using glass microspheres: Safety and survival outcomes from a 531-patient multicenter study. *J Nucl Med*. 2016; 57(5):665-671.
-

Federal and State law, as well as contract language including definitions and specific coverage provisions/exclusions, and Medical Policy take precedence over Clinical UM Guidelines and must be considered first in determining eligibility for coverage. The member's contract benefits in effect on the date that services are rendered must be used. Clinical UM Guidelines, which address medical efficacy, should be considered before utilizing medical opinion in adjudication. Medical technology is constantly evolving, and we reserve the right to review and update Clinical UM Guidelines periodically. Clinical UM guidelines are used when the plan performs utilization review for the subject. Due to variances in utilization patterns, each plan may choose whether or not to adopt a particular Clinical UM Guideline. To determine if review is required for this Clinical UM Guideline, please contact the customer service number on the back of the member's card.

No part of this publication may be reproduced, stored in a retrieval system or transmitted, in any form or by any means, electronic, mechanical, photocopying, or otherwise, without permission from the health plan.

© CPT Only – American Medical Association

Healthy Blue is a Medicaid product offered by Missouri Care, Inc., a MO HealthNet Managed Care health plan contracting with the Missouri Department of Social Services. Healthy Blue is administered statewide by Missouri Care, Inc. and administered in the Kansas City service region by Missouri Care, Inc. in cooperation with Blue Cross and Blue Shield of Kansas City. Missouri Care, Inc. and Blue Cross and Blue Shield of Kansas City are both independent licensees of the Blue Cross and Blue Shield Association.

 Locoregional Techniques for Treating Primary and Metastatic Liver Malignancies

20. Kennedy A, Bester L, Salem R, et al; NET-Liver-Metastases Consensus Conference. Role of hepatic intra-arterial therapies in metastatic neuroendocrine tumours (NET): guidelines from the NET-Liver-Metastases Consensus Conference. *HPB (Oxford)*. 2015; 17(1):29-37.
21. Kulik L, Heimbach JK, Zaiem F, et al. Therapies for patients with hepatocellular carcinoma awaiting liver transplantation: A systematic review and meta-analysis. *Hepatology*. 2018; 67(1):381-400.
22. Kutlu OC, Chan JA, Aloia TA, et al. Comparative effectiveness of first-line radiofrequency ablation versus surgical resection and transplantation for patients with early hepatocellular carcinoma. *Cancer*. 2017; 123(10):1817-1827.
23. Lievens Y, Guckenberger M, Gomez D, et al. Defining oligometastatic disease from a radiation oncology perspective: An ESTRO-ASTRO consensus document. *Radiother Oncol*. 2020; 148:157-166.
24. National Comprehensive Cancer Network® (NCCN) Practice Guidelines in Oncology™. © 2023 National Comprehensive Cancer Network, Inc. For additional information, visit the NCCN website: <http://www.nccn.org>. Accessed on April 23, 2023.
 - Biliary Tract Cancers (V2.2023). Revised March 10, 2023.
 - Breast Cancer (V.4.2023). Revised March 23, 2023.
 - Cervical Cancer (V.1.2023). Revised January 6, 2023.
 - Colon Cancer (V.1.2023). Revised March 29, 2023.
 - Gastrointestinal Stromal Tumors (V.2.2022). Revised September 1, 2022.
 - Hepatocellular Carcinoma (V1.2023). Revised March 10, 2023
 - Kidney Cancer (V4.2023). Revised January 18, 2023.
 - Melanoma: Uveal (V2.2022) Revised April 5, 2022.
 - Neuroendocrine and Adrenal Tumors (V.2.2022). Revised December 21, 2022.
 - Occult Primary (Cancer of Unknown Primary [CUP]. (V3.2023). Revised December 21, 2022.
 - Rectal Cancer (V.1.2023). Revised March 29, 2023.
 - Soft Tissue Sarcoma (V.1.2023). Revised March 13, 2023.
25. Oliveri RS, Wetterslev J, Gluud C. Transarterial (chemo) embolisation for unresectable hepatocellular carcinoma. *Cochrane Database Syst Rev*. 2011;(3):CD004787.
26. Organ Procurement and Transplantation Network. United Network for Organ Sharing (UNOS). Policy: 9 Allocation of Livers and Liver-Intestines. Effective March 16, 2023. Available at: <http://optn.transplant.hrsa.gov/governance/policies/>. Accessed on May 18, 2023.
27. Riemsma RP, Bala MM, Wolff R, Kleijnen J. Electro-coagulation for liver metastases. *Cochrane Database Syst Rev*. 2013;(5):CD009497.
28. Riemsma RP, Bala MM, Wolff R, Kleijnen J. Transarterial (chemo)embolization versus no intervention or placebo intervention for liver metastases. *Cochrane Database Syst Rev*. 2013;(4):CD009498.
29. Solbiati, L. Humanitas Hospital. The HistoSonics System for Treatment of Primary and Metastatic Liver Tumors Using Histotripsy (#HOPE4LIVER). NCT04573881. Last updated on April 6, 2023. Available at:

Federal and State law, as well as contract language including definitions and specific coverage provisions/exclusions, and Medical Policy take precedence over Clinical UM Guidelines and must be considered first in determining eligibility for coverage. The member's contract benefits in effect on the date that services are rendered must be used. Clinical UM Guidelines, which address medical efficacy, should be considered before utilizing medical opinion in adjudication. Medical technology is constantly evolving, and we reserve the right to review and update Clinical UM Guidelines periodically. Clinical UM guidelines are used when the plan performs utilization review for the subject. Due to variances in utilization patterns, each plan may choose whether or not to adopt a particular Clinical UM Guideline. To determine if review is required for this Clinical UM Guideline, please contact the customer service number on the back of the member's card.

No part of this publication may be reproduced, stored in a retrieval system or transmitted, in any form or by any means, electronic, mechanical, photocopying, or otherwise, without permission from the health plan.

© CPT Only – American Medical Association

Healthy Blue is a Medicaid product offered by Missouri Care, Inc., a MO HealthNet Managed Care health plan contracting with the Missouri Department of Social Services. Healthy Blue is administered statewide by Missouri Care, Inc. and administered in the Kansas City service region by Missouri Care, Inc. in cooperation with Blue Cross and Blue Shield of Kansas City. Missouri Care, Inc. and Blue Cross and Blue Shield of Kansas City are both independent licensees of the Blue Cross and Blue Shield Association.

<https://clinicaltrials.gov/ct2/show/study/NCT04573881?term=%23HOPE4LIVER&draw=1&rank=1>.

Accessed on May 18, 2023.

30. Swierz MJ, Storman D, Riemsma RP, et al. Percutaneous ethanol injection for liver metastases. *Cochrane Database Syst Rev.* 2020; 2(2):CD008717.
31. TheraSphere. PI Label. Surrey, UK. Biocompatibles UJNK Ltd. 2014. Available at: <https://www.bostonscientific.com/en-US/products/cancer-therapies/therasphere-y90-glass-microspheres/therasphere-y90-microspheres-brief-summary.html>. Accessed on May 18, 2023.
32. Townsend A, Price T, Karapetis C. Selective internal radiation therapy for liver metastases from colorectal cancer. *Cochrane Database Syst Rev.* 2009;(4):CD007045.
33. United States Nuclear Regulatory Commission (U.S. NRC). Microsphere Brachytherapy Sources and Devices. Licensing Guidance: ThereSphere® and SIR-Spheres® Yttrium-90 Microspheres. Revised November 8, 2019. Available at: <https://www.nrc.gov/docs/ML1920/ML19204A272.pdf>. Accessed on May 18, 2023.
34. Weis S, Franke A, Berg T, et al. Percutaneous ethanol injection or percutaneous acetic acid injection for early hepatocellular carcinoma. *Cochrane Database Sys Rev.* 2015;(1):CD006745.
35. Weis S, Franke A, Mössner J, et al. Radiofrequency (thermal) ablation versus no intervention or other interventions for hepatocellular carcinoma. *Cochrane Database Sys Rev.* 2013;(12):CD003046.
36. Wong SL, Mangu PB, Choti MA, et al. American Society of Clinical Oncology 2009 clinical evidence review on radiofrequency ablation of hepatic metastases from colorectal cancer. *J Clin Oncol.* 2010; 28(3):493-508.
37. Ziemlewicz T, Cho C. The HistoSonic System for Treatment of Primary and Metastatic Liver Tumors Using Histotripsy (#HOPE4LIVER US). NCT04572633. Last updated on November 2, 2021. Available at: <https://clinicaltrials.gov/ct2/show/study/NCT04572633?term=%23HOPE4LIVER&draw=1&rank=2>. Accessed on May 18, 2023.

Websites for Additional Information

1. American Cancer Society. Available at: www.cancer.org. Accessed on May 18, 2023.
2. National Cancer Institute. Cancer topics Available at: <http://www.cancer.gov/cancertopics>. Accessed on May 18, 2023.
 - Adult Primary Liver Cancer (PDQ®): Treatment. Last updated January 20, 2023.
 - Childhood Liver Cancer Treatment (PDQ). Last updated April 7, 2023.
 - Colon Cancer Treatment (PDQ). Last updated May 11, 2023.
 - Intraocular (Uveal) Melanoma Treatment (PDQ). Last updated May 12, 2023.
 - Pancreatic Neuroendocrine Tumors (Islet Cell Tumors) Treatment (PDQ). Last updated August 19, 2022.
 - Rectal Cancer Treatment (PDQ). Last updated May 11, 2022.
3. U.S. National Institutes of Health (NIH). Clinical trials. Available at: <https://clinicaltrials.gov/ct2/search>. Accessed on May 18, 2023.

Federal and State law, as well as contract language including definitions and specific coverage provisions/exclusions, and Medical Policy take precedence over Clinical UM Guidelines and must be considered first in determining eligibility for coverage. The member's contract benefits in effect on the date that services are rendered must be used. Clinical UM Guidelines, which address medical efficacy, should be considered before utilizing medical opinion in adjudication. Medical technology is constantly evolving, and we reserve the right to review and update Clinical UM Guidelines periodically. Clinical UM guidelines are used when the plan performs utilization review for the subject. Due to variances in utilization patterns, each plan may choose whether or not to adopt a particular Clinical UM Guideline. To determine if review is required for this Clinical UM Guideline, please contact the customer service number on the back of the member's card.

No part of this publication may be reproduced, stored in a retrieval system or transmitted, in any form or by any means, electronic, mechanical, photocopying, or otherwise, without permission from the health plan.

© CPT Only – American Medical Association

Healthy Blue is a Medicaid product offered by Missouri Care, Inc., a MO HealthNet Managed Care health plan contracting with the Missouri Department of Social Services. Healthy Blue is administered statewide by Missouri Care, Inc. and administered in the Kansas City service region by Missouri Care, Inc. in cooperation with Blue Cross and Blue Shield of Kansas City. Missouri Care, Inc. and Blue Cross and Blue Shield of Kansas City are both independent licensees of the Blue Cross and Blue Shield Association.

Index

- Colorectal Cancer
- Cryoablation
- Hepatic Metastases
- Hepatic Tumors
- Hepatocellular Carcinoma
- Immunoembolization
- Liver Tumors
- Metastatic Liver Tumors
- Microwave Ablation
- Percutaneous Ethanol Injection (PEI)
- Radioembolization
- Radiofrequency Ablation (RFA)
- Selective Internal Radiation Therapy
- Selective Internal Radiation Treatment
- SIR-Spheres
- SIRT
- Surgical Ablation
- TheraSphere
- Transcatheter Arterial Chemoembolization (TACE)
- Transcatheter Arterial Embolization (TAE)
- Transarterial Radioembolization (TARE)
- yttrium-90 Microspheres

The use of specific product names is illustrative only. It is not intended to be a recommendation of one product over another, and is not intended to represent a complete listing of all products available.

History

Status	Date	Action
	09/27/2023	Updated Coding section with 10/01/2023 HCPCS changes; added C9790.
Revised	05/11/2023	Medical Policy & Technology Assessment Committee (MPTAC) review. Revised title and criteria to remove references to surgical resection. Removed requirements 1) 3 or less lesions to be treated and 2) 6 months have elapsed prior to repeat procedure under locally ablative techniques statement.

Federal and State law, as well as contract language including definitions and specific coverage provisions/exclusions, and Medical Policy take precedence over Clinical UM Guidelines and must be considered first in determining eligibility for coverage. The member's contract benefits in effect on the date that services are rendered must be used. Clinical UM Guidelines, which address medical efficacy, should be considered before utilizing medical opinion in adjudication. Medical technology is constantly evolving, and we reserve the right to review and update Clinical UM Guidelines periodically. Clinical UM guidelines are used when the plan performs utilization review for the subject. Due to variances in utilization patterns, each plan may choose whether or not to adopt a particular Clinical UM Guideline. To determine if review is required for this Clinical UM Guideline, please contact the customer service number on the back of the member's card.

No part of this publication may be reproduced, stored in a retrieval system or transmitted, in any form or by any means, electronic, mechanical, photocopying, or otherwise, without permission from the health plan.

© CPT Only – American Medical Association

Healthy Blue is a Medicaid product offered by Missouri Care, Inc., a MO HealthNet Managed Care health plan contracting with the Missouri Department of Social Services. Healthy Blue is administered statewide by Missouri Care, Inc. and administered in the Kansas City service region by Missouri Care, Inc. in cooperation with Blue Cross and Blue Shield of Kansas City. Missouri Care, Inc. and Blue Cross and Blue Shield of Kansas City are both independent licensees of the Blue Cross and Blue Shield Association.

		Removed requirements 1) 3 or few encapsulated nodules and each nodule is less than or equal to 5 centimeters 2) no evidence of severe renal function 3) no evidence of portal vein impairment under arterially directed techniques to treat unresectable primary hepatocellular carcinoma statement. Revised criteria <i>no evidence of extrahepatic metastases</i> to <i>no or minimal extrahepatic metastases</i> under arterially directed and locally ablative techniques to treat unresectable primary hepatocellular carcinoma statement. Added MN indication for SIRT/TARE as a treatment of liver only metastasis from uveal (ocular) melanoma. Added MN indication for SIRT/TARE as a treatment of colorectal cancer when criteria are met. Removed requirement of no evidence of severe renal function impairment from bridge to liver transplantation criteria. Added note to arterially directed therapies medically necessary statement referring to NMN types of TACE therapy. Revised NMN statements. Reformatted all locally ablative and arterially directed technique criteria. Updated Description, Discussion and References section. Updated Coding section, reformatted and removed codes 47120, 47122, 47125, 47130 & associated ICD-10-PCS codes for excision no longer addressed; added ICD-10-PCS code 04L33DZ.
Reviewed	02/16/2023	MPTAC review. Revised Description, Discussion and References sections.
Reviewed	02/17/2022	MPTAC review. Updated Discussion and References sections.
Revised	11/11/2021	MPTAC review. Revised the clinical indications to add a not medically necessary statement for histotripsy. Updated Description, Discussion and References sections. Updated Coding section with 01/01/2022 CPT changes; added 0686T.
Revised	02/11/2021	MPTAC review. Revised not medically necessary for all liver related indications position statement to include immunoembolization. Revised Description, Discussion, Definitions and References sections. Reformatted and updated Coding section.
Revised	02/20/2020	MPTAC review. Revised term SIRT to SIRT/TARE within all clinical indications statements. Reordered clinical indications statements without change in intents. Revised Description, Discussion, Definitions and References sections.
Revised	08/22/2019	MPTAC review. Moved content of CG-SURG-80 Transcatheter Arterial Chemoembolization (TACE) and Transcatheter Arterial Embolization (TAE) for Treating Primary or Metastatic Liver Tumors and CG-THER-RAD-04 Selective Internal Radiation Therapy (SIRT) of Primary or Metastatic Liver Tumors into document. Revised title from Locally Ablative Techniques for Treating Primary and Metastatic Liver Malignancies to Locoregional and

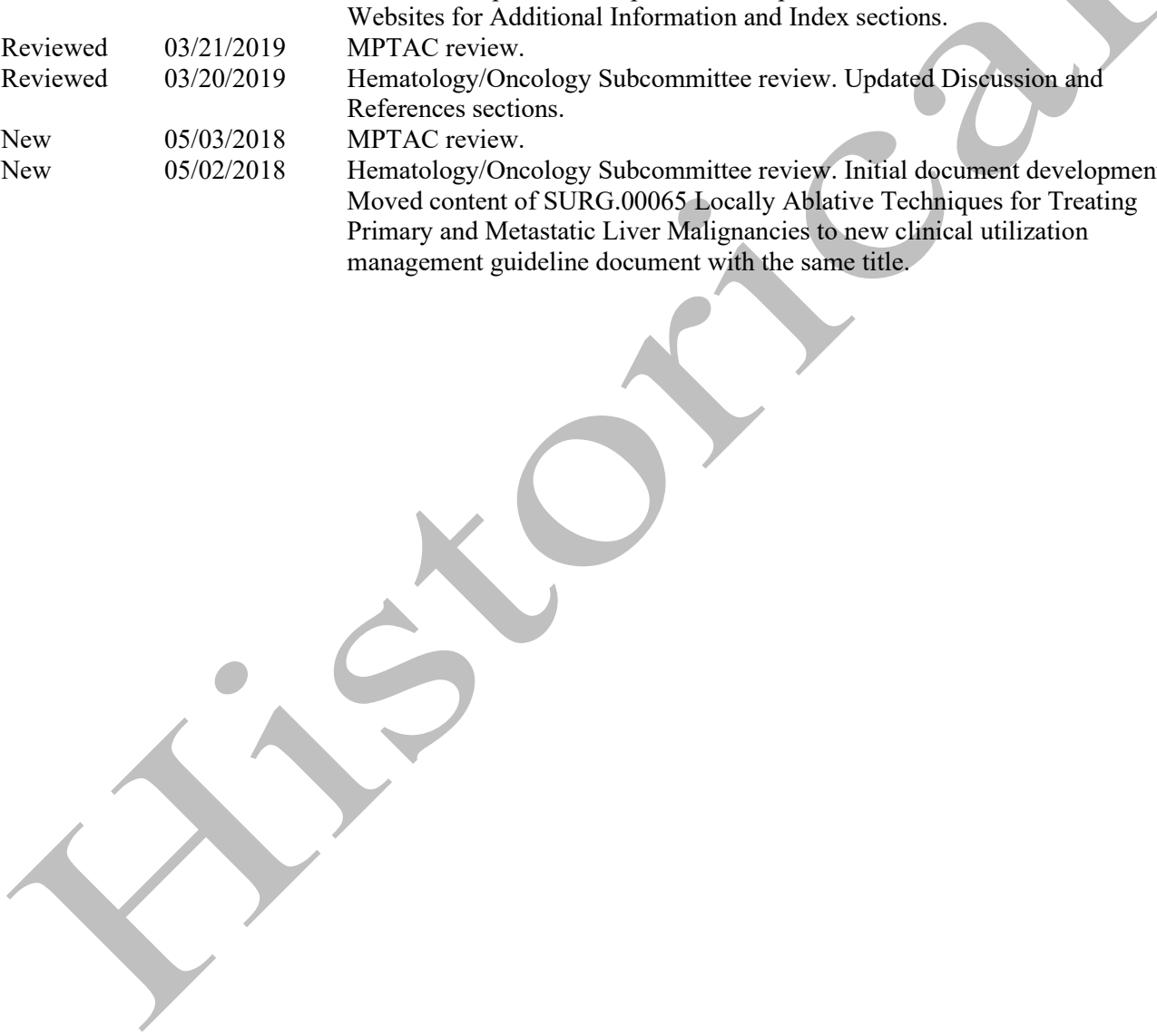
Federal and State law, as well as contract language including definitions and specific coverage provisions/exclusions, and Medical Policy take precedence over Clinical UM Guidelines and must be considered first in determining eligibility for coverage. The member's contract benefits in effect on the date that services are rendered must be used. Clinical UM Guidelines, which address medical efficacy, should be considered before utilizing medical opinion in adjudication. Medical technology is constantly evolving, and we reserve the right to review and update Clinical UM Guidelines periodically. Clinical UM guidelines are used when the plan performs utilization review for the subject. Due to variances in utilization patterns, each plan may choose whether or not to adopt a particular Clinical UM Guideline. To determine if review is required for this Clinical UM Guideline, please contact the customer service number on the back of the member's card.

No part of this publication may be reproduced, stored in a retrieval system or transmitted, in any form or by any means, electronic, mechanical, photocopying, or otherwise, without permission from the health plan.

© CPT Only – American Medical Association

Healthy Blue is a Medicaid product offered by Missouri Care, Inc., a MO HealthNet Managed Care health plan contracting with the Missouri Department of Social Services. Healthy Blue is administered statewide by Missouri Care, Inc. and administered in the Kansas City service region by Missouri Care, Inc. in cooperation with Blue Cross and Blue Shield of Kansas City. Missouri Care, Inc. and Blue Cross and Blue Shield of Kansas City are both independent licensees of the Blue Cross and Blue Shield Association.

		Surgical Techniques for Treating Primary and Metastatic Liver Malignancies. Added Percutaneous Ethanol Injection (PEI) and Radiofrequency Ablation (RFA) as medically necessary procedures in those who may become eligible for liver transplantation. Updated Description, Discussion, References, Websites for Additional Information and Index sections.
Reviewed	03/21/2019	MPTAC review.
Reviewed	03/20/2019	Hematology/Oncology Subcommittee review. Updated Discussion and References sections.
New	05/03/2018	MPTAC review.
New	05/02/2018	Hematology/Oncology Subcommittee review. Initial document development. Moved content of SURG.00065 Locally Ablative Techniques for Treating Primary and Metastatic Liver Malignancies to new clinical utilization management guideline document with the same title.



Federal and State law, as well as contract language including definitions and specific coverage provisions/exclusions, and Medical Policy take precedence over Clinical UM Guidelines and must be considered first in determining eligibility for coverage. The member's contract benefits in effect on the date that services are rendered must be used. Clinical UM Guidelines, which address medical efficacy, should be considered before utilizing medical opinion in adjudication. Medical technology is constantly evolving, and we reserve the right to review and update Clinical UM Guidelines periodically. Clinical UM guidelines are used when the plan performs utilization review for the subject. Due to variances in utilization patterns, each plan may choose whether or not to adopt a particular Clinical UM Guideline. To determine if review is required for this Clinical UM Guideline, please contact the customer service number on the back of the member's card.

No part of this publication may be reproduced, stored in a retrieval system or transmitted, in any form or by any means, electronic, mechanical, photocopying, or otherwise, without permission from the health plan.

© CPT Only – American Medical Association

Healthy Blue is a Medicaid product offered by Missouri Care, Inc., a MO HealthNet Managed Care health plan contracting with the Missouri Department of Social Services. Healthy Blue is administered statewide by Missouri Care, Inc. and administered in the Kansas City service region by Missouri Care, Inc. in cooperation with Blue Cross and Blue Shield of Kansas City. Missouri Care, Inc. and Blue Cross and Blue Shield of Kansas City are both independent licensees of the Blue Cross and Blue Shield Association.